

# Third Molar Impaction- A Review

**Divya.T, Themozhi M.S.**

*Department of Anatomy,  
Saveetha Dental College,  
Tamilnadu*

## **Abstract**

The most commonly performed surgical procedure in most oral and maxillofacial surgery practices is the removal of impacted third molars. Extensive training, skill, and experience allow this procedure to be performed in a traumatic fashion with local anaesthesia, sedation, or general anaesthesia. In present generation the third molars have impacted due to inadequate space in the mandible. This is due to evolution of mandible. Our ancestors had larger and wider mandible but now the present generation has smaller and less wide mandible resulting in molar impaction. This article is about the surgical removal of impacted third molars.

**Key words:** Third molars, Impaction, Surgery

## **INTRODUCTION**

A wisdom tooth (or third molar), refers to one of the molars in humans. Wisdom teeth generally appear between the ages of 17 and 25. [1] Most adults have four wisdom teeth, but it is possible to have fewer or more, in which case the extras are called supernumerary teeth. Wisdom teeth commonly affect other teeth as they develop, becoming impacted or "coming in sideways." They are often extracted when this occurs. Wisdom teeth are vestigial third molars that used to help human ancestors in grinding down plant tissue. The common postulation is that the skulls of human ancestors had larger jaws with more teeth, which were possibly used to help chew down foliage to compensate for a lack of ability to efficiently digest the cellulose that makes up a plant cell wall. As human diets changed, smaller jaws gradually evolved, yet the third molars, or "wisdom teeth", still commonly develop in human mouths. [2] Wisdom teeth have long been identified as a source of problems and continue to be the most commonly impacted teeth in the human mouth. The oldest known impacted wisdom tooth belonged to a European woman of the Magdalenian period (18,000–10,000 BC).[3] A lack of room to allow the teeth to erupt results in a risk of periodontal disease and caries that increases with age.[4] Only a small minority of adults age 65 years or older maintain the teeth without caries or periodontal disease and 13% maintain unimpacted wisdom teeth without caries or periodontal disease.[5] Impacted wisdom teeth are classified by the direction and depth of impaction, the amount of available space for tooth eruption, and the amount soft tissue or bone (or both) that covers them. The classification structure allows clinicians to estimate the probabilities of impaction, infections and complications associated with wisdom teeth removal.[6] Wisdom teeth are also classified by the presence (or absence) of symptoms and disease.[7] Treatment of an erupted wisdom tooth is the same as any other tooth in the mouth. If impacted, treatment can be localized to the infected tissue overlying the impaction [8], extraction [9] or coronectomy. [10]

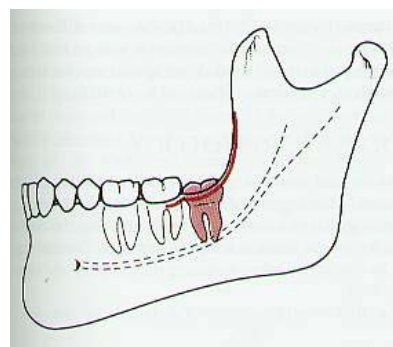
## **CLASSIFICATION**

Pell and Gregory classification

- Based on the amount of tooth covered by the anterior border of the ramus (1,2,or 3).
- The depth of the impaction relative to the adjacent tooth (A,B,or C).
- Helpful in predicting surgical difficulty.

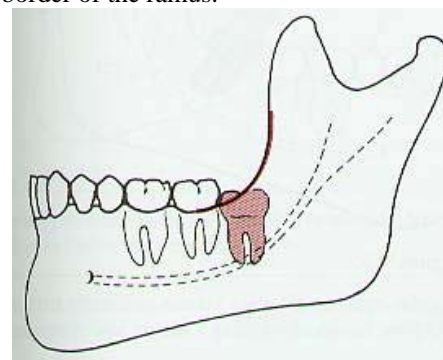
Class I

Class I 3rd molar impaction: Situated anterior to the anterior border of the ramus.



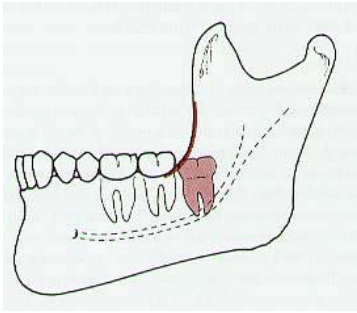
Class II

Class II 3rd molar impaction: Crown ½ covered by the anterior border of the ramus.



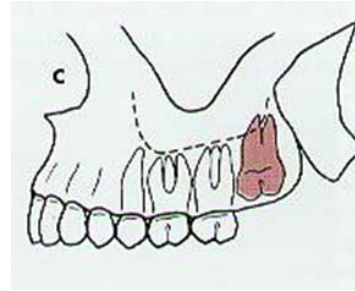
**Class III**

Class III 3rd molar impaction: Crown fully covered by the anterior border of the ramus.



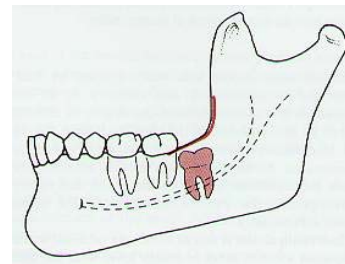
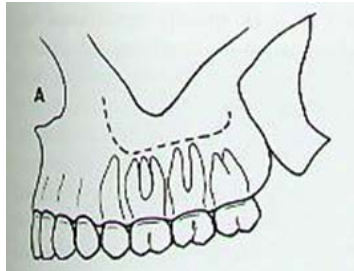
**Class C**

Class C maxilla 3rd molar impaction: The occlusal plane of the impacted tooth is apical to the cervical line of the adjacent tooth.

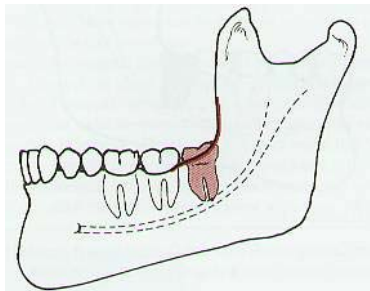


**Class A**

Class A maxilla 3rd molar impaction: The occlusal plane of the impacted tooth is at the same level as the adjacent tooth.

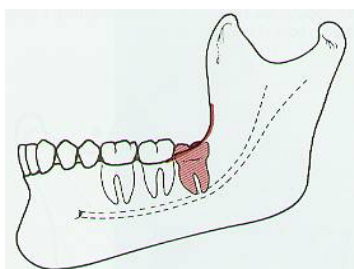
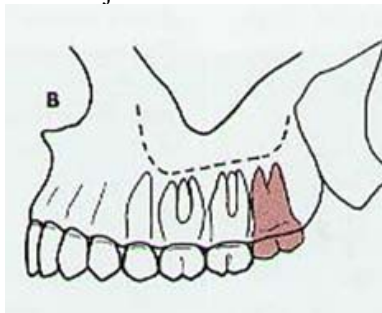


[11]



**Class B**

Class B maxilla 3rd molar impaction: The occlusal plane of the impacted tooth is between the occlusal plane and the cervical line of the adjacent tooth.



**CAUSE**

The cause of mandibular third molar impaction is said to be due to inadequate space between the distal of the second mandibular molar and the anterior border of the ascending ramus of the mandible. The amount of space is determined primarily by facial growth. It was hypothesized that those with predominantly horizontal (brachyfacial) would have lower incidence of mandibular third molar impaction compared with those with a predominantly vertical growth pattern (dolichofacial).

**METHODS OF EXTRACTION**

Surgical removal of impacted mandibular third molars should be carried out well before the age of 24 years, especially for female patients. Older patients are at greater risk of postoperative complications and permanent sequelae. A surgeon's lack of experience could also be a major factor in the development of postoperative complications. Several common steps apply to the removal of all impacted teeth. Adequate flaps must be reflected for accessibility, overlying bone must be removed for exposure, exposed teeth may be sectioned, sectioned teeth are delivered, and finally the wound must be closed. These procedures are outlined initially as they apply to third molar removal in general, and then a discussion of specific situations involving different classifications of impactions is presented. Infiltration anaesthesia placed in the area overlying third molar impactions is used in addition to block anaesthesia. Accessibility is a key issue in removal of impacted teeth. A full-thickness mucoperiosteal flap must be elevated to allow for visualization and placement of retractors, drilling equipment, elevators, and forceps. The lower third molar incision most commonly used is an envelope flap that extends from the mesial of the first molar to the ramus with lateral divergence of the posterior extension to avoid lingual nerve injury. An alternative

incision that allows for increased exposure and less trauma to the reflected tissue is a three cornered flap. With this flap an anterior vertical releasing incision at the distal aspect of the first or second molar is made. In either flap design the incision must be full thickness. The extent of the flap reflection should be limited to the external oblique ridge laterally. Reflecting beyond this point leads to increased dead space and more edema. The flap must be raised in a subperiosteal plane without tears. A Minnesota retractor is placed just lateral to the external oblique ridge and stabilized against the lateral surface of the mandible. The retractor should be held by a few fingers at its distal end so that it can be toed out laterally without the hand holding it blocking the vision of the operator. The need for bone removal with a drill or periosteal elevator can be established at this point. After the need for and extent of bone removal is determined, a hand piece with adequate speed and torque is used to remove bone from the occlusal aspect of the tooth. Buccal and distal bone removal is performed down to the cervical line of the impaction. This bone removal should be in the form of a trough and should not involve the full thickness of the lateral cortical plate of the mandible. Only enough buccal cortical bone should be removed as is needed for access for elevating, sectioning, and purchase point placement. After initial bone removal the tooth should be elevated with a #301 elevator. If the entire tooth as a unit can be elevated slightly at this juncture it lessens the chance of fracturing a root tip and finding it nonmobile when an attempt to recover it proceeds. With respect to upper third molar teeth, the overlying bone in the maxilla is typically thin and usually can be removed with a Potts elevator, periosteal elevator, or chisel using hand pressure. When sufficient access is obtained, the need for sectioning of an impacted tooth can be determined. Several key points should be mentioned regarding tooth sectioning in general. When it is determined that a tooth should be sectioned vertically (as in the case of a mesioangular impacted lower third molar), the line of sectioning generally should be determined and then moved approximately 1.5 to 2 mm more anterior than initially felt necessary. This adjustment helps prevent inadvertently sectioning the tooth too distally, which often occurs as a result of the obstructing position of the second molar. The cut through the tooth should proceed to just short of the lingual surface to protect the lingual nerve. Vertical cuts should be placed carefully so that the line of sectioning does not angle from the perpendicular. If the sectioning line varies from the perpendicular, there are cases in which the segments are wider at the bottom (in the case of the horizontal impaction) than at the top and elevation is hindered. Purchase points also can be placed at the sectioning stage. A Crane pick or Cogswell B elevator is used to elevate teeth that have purchase points placed. The purchase points should be deep enough and placed in a substantial enough portion of tooth structure so that the elevation of the segment occurs rather than fracture. It should be remembered that a Cogswell B elevator has a smooth surface at the tip and is less likely to cause a fracture when used to engage the purchase point. A Crane pick is flat surfaced at the four sides of the tip and

frequently causes fracturing when placed in a purchase point and force applied. When adequate bone has been removed and the tooth is sectioned into manageable segments, the tooth is delivered with elevators. The #301, Crane pick, and Cogswell B elevators serve this function well. Paired, sharp pointed elevators such as the Cryer or Winter elevators are capable of applying extreme force, and their use can be avoided if the drill is used to prepare an unimpeded pathway for delivery of the sectioned tooth. Excessive force can result in unfavourable root fracture, buccal or lingual bone loss, damage to the adjacent second molar, or even fracture of the mandible. Because impacted teeth have never sustained occlusal loading, their periodontal ligament space is wider and less tenacious, and they can be easily displaced if appropriate bone is removed and elevation forces are applied in a proper direction. Most impacted maxillary third molars are easily elevated with a #301 elevator after removal of overlying bone. A Potts elevator can be used after initial elevation provides an entry point for this elevator. The Minnesota retractor or periosteal elevator always should be placed distal to the impacted maxillary third molar on final elevation so that it cannot be displaced under the flap and into the infratemporal fossa. Although not popular in the United States, a Laster retractor is an ideal retractor because it engages the tuberosity, provides excellent access, and prevents displacement of the tooth. After the third molar is removed the socket must be debrided of all particulate bone and remaining tooth pieces. Careful irrigation under the reflected flap prevents retention of debris in this area, which can complicate healing. A rongeur, bone file, or bur can be used to smooth any sharp or rough edges of bone. All follicular fragments should be removed with a curette and mosquito hemostat. Primary closure of lower third molar sites is recommended, and although resorbable sutures suffice, some surgeons prefer nonresorbable sutures, which provide greater and longer lasting tensile stress and encourage patients to return for a postoperative visit for suture removal. The benefit of routine follow-up for third molar patients was recently questioned by Sittavornwong and colleagues however. Some surgeons are proponents of tight suturing to assist in hemostasis, whereas other surgeons believe that loose suturing leads to less edema and allows for drainage of the wound. Frequently, upper third molar sites do not require suturing because the wound is held in proper position by gravity and the surrounding soft tissues. The specific technique for tooth sectioning varies depending on the angulation of the impacted lower third molar. In the case of the mesioangular impaction, the crown is exposed and a buccal and distal trough is created. Some mesioangular impactions can be removed simply by placing a purchase point in the mesial portion of the tooth at the cervical line and elevating with a Crane pick or a Cogswell B elevator. In other cases the distal aspect of the crown is sectioned or the distal and mesial root portions are sectioned and the distal segment of the tooth is delivered, after which the remainder of the tooth is elevated with a #301 elevator. In the case of a horizontal impaction, adequate bone is removed to allow for exposure and the crown is sectioned from the roots in a

vertical plane, with care taken not to allow the cut to drift distally and create a segment of crown that is larger at the bottom than at the top. At times the crown section resists delivery, and this process can be helped by sectioning the crown segment in a longitudinal fashion. After removing the crown, the roots can be elevated with a purchase point at the superior aspect of the upper root with elevation of both roots simultaneously or the delivery of each root individually after sectioning (Fig. 12B). In all cases of sectioning the cut should be kept within the tooth structure to prevent damage to the lingual tissues or the inferior alveolar canal. Vertically impacted mandibular third molars can be removed by several techniques depending on the depth of the impaction, the root development, and the age of the patient. When dealing with a young patient, when the bone is somewhat flexible and root development is incomplete, the tooth often can be exposed with the creation of a buccal and distal trough followed by elevation without sectioning. A purchase point is helpful in these situations. In cases in which simple elevation is not possible, the distal aspect of the crown can be sectioned and removed followed by the elevation of the remainder of the crown and root structure if the roots are fused. If the root formation is complete and divergent, it may be best to section the mesial and distal roots, with removal of the distal root followed by the mesial root. The operator should attempt to preserve as much of a ‘handle’ as possible because dealing with small segments that have not been luxated is where most difficulty is encountered in third molar removal. A deep, vertically impacted third molar below the cervical line of the second molar and fully covered with bone can present a difficult challenge for the surgeon. In such cases the tooth should be exposed, a buccal and distal trough created, and the tooth elevated en masse with subsequent sectioning of the crown in a horizontal fashion. The roots can be elevated in one piece or sectioned and delivered as separate units with the elevation of the distal root preceding that of the mesial. It is important to maintain as much root structure as possible to serve as a ‘handle’ for elevation. Distoangular mandibular impactions are considered by most surgeons to be the most difficult third molar impactions to remove. The pathway of delivery for an elevated distoangular impaction is into the vertical ramus of the mandible. The goal of the technique for removal of these teeth is to create an adequate buccal and distal trough around the full crown of the tooth to a depth below the cervical line. At this point elevation of the tooth should be attempted. If some movement is obtained, the distal portion of the crown or the complete crown can be sectioned in a horizontal fashion from the roots and removed. The sectioned crown may have to be sectioned again if inadequate space is available for its removal. It is preferable in this case to section the tooth segments further as needed rather than to remove more bone. The remaining root segment along with the mesial portion of crown, in cases in which the distal portion has been eliminated as a first step, can be elevated and removed. Additional sectioning of this fragment also may be necessary to create segments that are of a size that can be removed from the bony cavity created. Additional sectioning of tooth is

preferable to additional bone removal at this point because preservation of the structural integrity of the lower jaw is maintained. If the complete crown has been removed, the remaining root segments can be dealt with as a single unit. If tooth sectioning is required, the distal root should be elevated before the mesial root throughout this article, no mention or recommendation has been made by the author (SEF) for Cryer, Winter, or Cogswell A elevators. These instruments have the ability to create significant forces, and unless they are cautiously applied they can damage the teeth or bone with potential unexpected tooth, alveolar, or mandibular fracture. A sharp, pointed elevator such as a Cryer or a Winter can be useful in removing bone in the furcation that is retaining a root fragment, but a root fragment so elevated is pushed against an intact wall of bone and is more likely to fracture or defy removal than it would if removed in a mesial direction with the assistance of a well-placed purchase point as needed. The use of a Cogswell A or other broad elevator between the buccal surface of the impacted tooth and the external oblique ridge to loosen or elevate a tooth or root segment is a common practice in third molar removal. This technique places the external oblique ridge, one of the buttresses of the mandible, and the lingual plate at risk for fracture. If such a fracture is unrecognized, a substantial late-presenting sequestrum or immediate lingual nerve injury is a possibility. Delicate instruments can be used to remove impacted third molars if adequate exposure, bone removal, and sectioning are performed. The author (SEF) is of the opinion that #301 and Heidebrink root tip elevator are preferred instruments for impacted tooth removal if adequate site preparation has been completed. In the case of maxillary third molar impactions, the envelope flap usually suffices but a vertical release at the distal aspect of the first molar frees the flap for extensive elevation if visualization of the tooth is impaired. Basic principles of flap design should be maintained, with the flap broader at the base than the apex, elevation of full-thickness mucoperiosteum, and wound closure over solid bone. A Minnesota retractor is used to retract the cheek and flap while protecting the flap and allowing visualization. If the incision is carried over the tuberosity and released in its full length, palatal retraction rarely is needed. Maxillary bone is much thinner and the underlying tooth usually can be exposed by removing this bone with a periosteal, Potts, or #301 elevator. Dense bone may require a hand piece and round bur, but this is rare. Sectioning of maxillary third molars should be avoided and considered only as a last resort because small segments can be displaced into the sinus or infratemporal fossa. The elevation of an impacted maxillary third molar is initially with a #301 elevator, and further elevation and delivery can be obtained with a Potts elevator. A Minnesota or Seldin retractor should always be placed below the cervical region of the crown before significant elevation to prevent displacement of the tooth into the infratemporal fossa. An end-cutting rongeur, a hemostat, and a Martin tooth-grasping forceps (KLS Martin, Jacksonville, Florida) are useful in the removal of teeth or fragments after adequate elevation. Once impacted tooth removal has been completed, the remaining bony cavity can be curetted to

remove any remnants of the follicle. The socket should be irrigated with saline and inspected. With respect to lower third molar teeth, if the IAN is visualized, it should be documented as intact or damaged in the operative note. If the lingual nerve is visualized, its condition also must be recorded appropriately. The upper third molar site is inspected for bony fragments, soft tissue, and the presence or absence of maxillary sinus communication. Sinus precautions should be prescribed if such an opening is recognized or suspected. The avoidance of forceful nose blowing and the prescription of antibiotics and nasal decongestants are mandatory to facilitate closure of the oro-antral communication. [12]

### RESULT

The third molar impaction is increasing in the present generation due to insufficient space in the upper and lower arch. This results in pain and so need arises for their extraction surgically. The present generation has a smaller mandible due to evolution. Crown is in contact below the equator to the coronal third of the second molar, partially impacted in the ramus, widest part of the crown (equator) is below the bone, roots are contacting or penetrating the mandibular canal, wall of the mandibular canal is unidentified, tooth is located in the middle between lingual and buccal walls; horizontal spatial position. Complicated extraction is anticipated and C2 value presumes moderate risk of inferior alveolar nerve damage [13].

### REFERENCE

- [1] Wisdom Teeth". American Association of Oral and Maxillofacial Surgeons. Retrieved 2010-09-28. "This generally occurs between the ages of 17 and 25"
- [2] Johnson, Dr. George B. "Evidence for Evolution". (Page 12) Txtwriter Inc. 8 Jun 2006.
- [3] Magdalenian Girl is a woman and therefore has oldest recorded case of impacted wisdom teeth" (Press release). Field Museum of Natural History. March 7, 2006. Retrieved February 15, 2013
- [4] Juodzbaly G, Daugela P (Apr-Jun 2013). "Mandibular Third Molar Impaction: Review of Literature and a Proposal of a Classification (review)". *J Oral Maxillofac Res* 4 (2): e1. doi:10.5037/jomr.2013.4201.
- [5] Marciani RD (2012). "Is there pathology associated with asymptomatic third molars (review)". *J Oral Maxillofac Surg* 70 (Suppl 1): 15–19. doi:10.1016/j.joms.2012.04.025
- [6] Juodzbaly G, Daugela P (Apr-Jun 2013). "Mandibular Third Molar Impaction: Review of Literature and a Proposal of a Classification *MaxillofacRes* 4 (2): e1. doi:10.5037/jomr.2013.420
- [7] Dodson TB (Sep 2012). "The management of the asymptomatic, disease-free wisdom tooth: removal versus retention. (review)". *Atlas Oral Maxillofac Surg clin North Am* 20 (2): 169–76. doi:10.1016/j.cxom.2012.06.005
- [8] Newman MG, Takei HH, Klokkevold PR, Carranza FA (2012). *Carranza's Clinical Periodontology*. Elsevier Saunders. ISBN 978-1-4377-0416-7
- [9] Pogrel MA (2012). "What are the Risks of Operative Intervention (review)". *J Oral Maxillofac Surg* 70 (Suppl 1): 33–36
- [10] Ghaemini H (2013). "Coronectomy may be a way of managing impacted third molars (systematic review)". *Evid Based Dent* 14 (2): 57–8. doi:10.1038/sj.ebd.6400939
- [11] www.jeemboomba.com
- [12] General Technique of Third Molar Removal Sam E. Farish, DMDa,b,\*, Gary F. Bouloux, MD, BDS, MDS, FRACDS, FRACDS(OMS)
- [13] Odusanya SA, Abayomi IO. Third molar eruption among rural Nigerians. *Oral Surg Oral Med Oral Pathol*. 1991 Feb;71(2):151-4. [Medline: 2003009] [doi: 10.1016/0030-4220(91)90457-N]