

Evaluation of “sublay” versus “onlay” mesh hernioplasty in ventral hernial repair

Dr. Ali Hussein Al-Tai,

Department of Maxillofacial surgery, College of dentistry, Kerbala University, Iraq.

Abstract

Ventral abdominal hernias are common surgical conditions which can be presented as emergency and elective cases. The repairs of ventral hernias have always been a big challenge to the surgeons. Mesh hernioplasty was considered as a golden choice to prevent or minimize incidence of recurrence but the question is where the surgeons should put the mesh sublay or onlay? This research aims to compare onlay versus sublay technique in ventral hernia repair in term of procedure and outcome. This study was conducted at surgical unit of Al-Imam Al-Hussein medical city. It is a prospective study of (120) patients submitted for ventral hernias repair. We collect our cases in one year from (1st January 2015 to 1st January 2016) and follow up continue until (January 2017). Sixty patients were managed by onlay (group A) mesh repair and 60 patients were managed by sublay (group B) mesh repair. Data collected in both groups was made with regards to operation time, placement and duration needed for drain removal, wound infection, and recurrence rate. Follow up every three month for 24 months was done. Data were analyzed using SPSS 18.0 software with, Fisher's exact test as appropriate; $p < 0.05$ was considered to be statistically significant. The research outcomes, in sublay group Seroma formation was found in two patients (3.33%) while 12(20%) in onlay group. Wound infection was found in one patient (1.66%) in sublay group while 6(10%) in onlay group. No septic mesh was removed in sublay while one mesh was removed in onlay type. In onlay group recurrence was found in 4 patients (6.66%) while there is no recurrence in the sublay group. In conclusion sublay mesh hernioplasty is a better alternative to onlay mesh hernioplasty for all forms of ventral hernia cases.

Key words:-Sublay, Onlay, Mesh Repair, Ventral Hernia, Umbilical hernia.

INTRODUCTION:

A ventral hernia is defined as a protrusion through the anterior abdominal wall fascia. These defects can be categorized as spontaneous, congenital or acquired or by their location on the abdominal wall to the epigastric hernias occur from the xiphoid process to the umbilicus, umbilical hernias occur at the umbilicus, paraumbilical and hypogastric hernias which are least common spontaneous hernias that occur below the umbilicus in the midline. Acquired hernias typically occur after surgical incisions and are therefore termed incisional hernias. Although not a true hernia, diastasis recti can present as a midline bulge. In this condition, the linea Alba is stretched, resulting in bulging at the medial margins of the rectus muscles. Abdominal wall diastasis can occur at other sites in addition to the midline. There is no fascial ring or hernia sac, and unless it is significantly symptomatic, surgical correction is avoided.

Based on national operative statistics, incisional hernias account for 15% to 20% of all abdominal wall hernias; umbilical and Epigastric hernias constitute 10% of hernias. Incisional hernias are twice as common in women as in men. There is no conclusive evidence demonstrating that the type of suture at the primary operation affects hernia formation [1]. Patient-related factors linked to ventral hernia formation include obesity, older age, male gender, sleep apnea, emphysema, and prostatism. It has been proposed that the same factors associated with destruction of the collagen in the lung result in poor wound healing, with increased hernia formation. Wound infection has been linked to hernia formation. The use of a suture to wound length ratio of 4: 1 has been shown to significantly reduce incisional hernia formation compared with the 1-cm bites

and 1-cm advancement suturing technique typically employed by most surgeons [2].

Whether the type of initial abdominal incision influences the incisional hernia rate remains controversial. As noted, the incidence of ventral herniation after midline laparotomy ranges from 3% to 20% and doubles if the operation is associated with a surgical site infection. A meta-analysis of 11 studies examining the incidence of ventral hernia formation after various types of abdominal incisions has concluded that the risk is 10.5% for midline, 7.5% for transverse, and 2.5% for Para median incisions [3]. A recently published prospective randomized trial has reported no difference in hernia formation in comparing midline versus transverse incisions after 1 year but noted a higher wound infection rate in the transverse incisions [4]. Given the likely similar rates of incisional hernia formation after transverse and midline incisions, the surgeon should plan the incision on the basis of the operative exposure desired to complete the procedure safely. Few data are available about the natural history of untreated ventral hernias. As noted, asymptomatic or minimally symptomatic inguinal hernias purposely observed during 2 years have a low incidence of complications [5]. Whether this paradigm applies for asymptomatic ventral or incisional hernias is unclear. Because there is no prospective cohort available to determine the natural history of untreated ventral hernias, most surgeons recommend that these hernias be repaired when discovered. The concept of “metastatic emphysema” that is the same processes that break down pulmonary tissue disturb normal fascia, was introduced by Dr. Raymond Read and appears to be well founded [6]. Incisional hernias are unique in that they are the only abdominal wall hernias that are considered to be iatrogenic.

It is one of the more common complications of abdominal surgical procedures and is a significant source of morbidity and loss of time from productive employment.

Successful repair of ventral hernias involve detailed understanding of anatomy regarding anterior abdominal wall and all its involved layers. The medial extension of the external oblique aponeurosis forms the anterior layer of the rectus sheath. At the midline, the two anterior rectus sheaths form the tendinous linea Alba. On either side of the linea Alba are the rectus abdominis muscles, whose fibers are directed longitudinally and run the length of the anterior abdominal wall. Below each rectus muscle lies the posterior layer of the rectus sheath, which also contributes to the linea Alba. Another important anatomic structure of the anterior abdominal wall is the arcuate line, which is located 3 to 6 cm below the umbilicus. The arcuate line delineates the point below which the posterior rectus sheath is absent. Above the arcuate line, the aponeurosis of the internal oblique muscle contributes to the anterior and posterior rectus sheaths, and the aponeurosis of the transversus abdominis muscle passes posterior to the rectus muscle to form the posterior rectus sheath. Below the arcuate line, the internal oblique and transversus abdominis aponeurosis pass completely anterior to the rectus muscle. The posterior rectus sheath below the arcuate line is composed of the transversalis fascia and peritoneum only.

Operative management of ventral hernias

For many years, the repair of ventral hernias was associated with a high recurrence rate. In more recent years, the introduction of synthetic prosthetic materials has provided the opportunity to perform a tension free repair, thereby reducing the rate of recurrence [7, 10].

Indications of surgery:-

- 1- Pain and discomfort.
- 2- Large hernial sac with small openings.
- 3- A history of recurrent attacks of subacute obstruction, incarceration and irreducibility.

- 4- For cosmetic reasons for a large and unsightly hernia.

Several procedures have been described for hernia repair and hernioplasty, with tension free mesh placement being vastly practiced in surgery [11]. Ventral hernia repair is among the most frequently performed surgical operation globally and the two operative techniques most frequently used in cases of ventral hernia are the onlay and sublay repair [12]. Although, it remains uncertain as to which repair technique has shown to be more successful [13]. Successful repair of abdominal hernias involves detailed understanding of anatomy regarding the anterior abdominal wall and all its involved layers [14]. Originally, high density mesh was introduced with onlay Mesh hernioplasty techniques followed by the introduction of mesh in sublay position which doesn't necessitate the need for suturing the mesh at the edges of the defect [15].

Mesh position in open ventral hernial repair

There are numerous options for mesh placement in ventral hernias as shown in Figure [1]. Only (Overlay) repair places the mesh on the anterior fascia, which typically involves dissection of flaps and primary closure of the fascia below the mesh. Inlay repair places the mesh in the hernia defect and secures the mesh circumferentially to the edges of the fascia. Sublay repair refers to Retrorectus or preperitoneal mesh placement. It is also commonly referred to as a Rives-Stoppa or retro-muscular repair. Finally, Underlay repair is when mesh is placed in the intraperitoneal position and secured to the anterior abdominal wall [16]. The underlay is also referred to as an open intraperitoneal onlay mesh (IPOM). In the laparoscopic literature an IPOM refers to an intraperitoneal mesh position which is equivalent to an underlay mesh position. Holihan performed an exhaustive meta-analysis of 21 available trials with almost 6000 patients comparing the above different mesh positions [16].

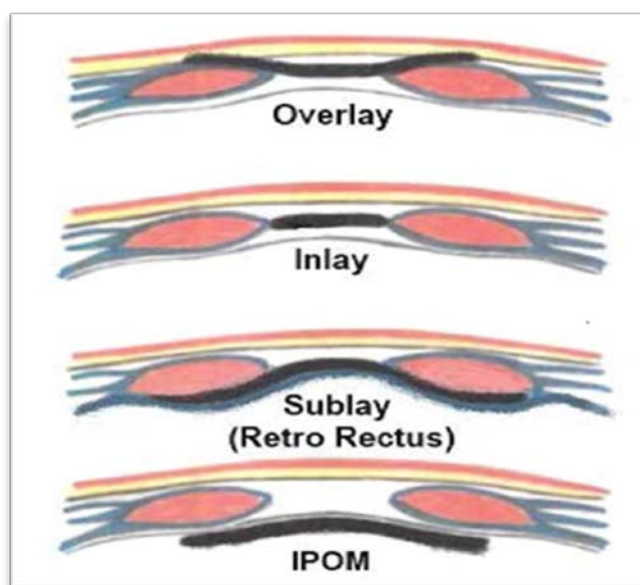
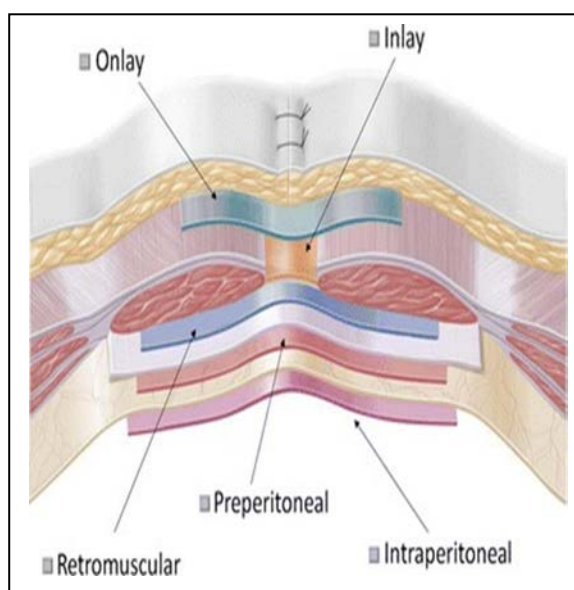


Figure (1) show: options for mesh positions in ventral hernias

The sublay mesh hernial repair are prefer as it reduce the recurrence rate by allowing larger pieces of prosthetic material to be used and incorporating intra-abdominal pressure to aid in keeping the mesh in place[17]. This procedure was first described by Renestopa, Jean Rives [18] and George Wantz [19]. This technique is considered by many surgeons to be the gold standard for the open repair of abdominal hernias [20- 23].

Aim of the study:-

To compare onlay versus sublay technique in ventral hernia repair in term of procedure and outcome

PATIENTS AND METHODS:-

This prospective comparative study was carried out on 120 patients of abdominal hernias admitted in General surgical unit of Al-Imam Al-Hussein medical city. We collect our cases in one year from (1st January 2015 to the 1st of January 2016) and follow up continue until (January 2017) and majority of our cases collected at the beginning of (2015) where the average of follow up was (1-2) years with 3 months visit interval which is followed by clinical examination and confirmed by Ultrasound.

In our study 60 cases of ventral hernias were managed by onlay (group A) mesh repair and 60 cases were managed by sublay (group B) mesh repair and we use same type of mesh (Polypropylene) in two groups and weather onlay or sublay technique chose according to the surgeon preference and experience. Follow-up of both groups were achieved by checking of the following parameters: - operative time, drain placement time which is one drain put subcutaneously, wound complications, and recurrence rate.

Inclusion criteria:-

All patients of both genders and with the following are included in the study:

1. Post laparotomy midline incisional hernias and recurrent hernias.
2. Primary hernias (umbilical, paraumbilical or epigastric) which was diagnosed on clinical examination and confirmed by U/S.

Exclusion criteria:-

We exclude from our study the following groups of patients who have different comorbidities with different degree of influence on the outcome of surgery according to the degree of severity of these comorbidities to make the procedure most probable cause of complications:

1. Morbidly obese patients with BMI>40Kg/m².
2. Patients with diabetes mellitus.
3. Patients with abdominal malignancy and cirrhosis with end stage liver disease.
4. All patients with chronic obstructive pulmonary disease (COPD) like asthma.
5. Patients with obstructive uropathy like benign prostatic hypertrophy (BPH).
6. Patients presented as emergency like strangulated hernia with signs of obstruction (abdominal distention, vomiting and absolute constipation) and those lack of follow up.
7. Pre-existing skin infection at the site of hernia with local signs of inflammation (redness, hotness and tenderness).

Operative Technique:

A/Sublay mesh repair:-

The principles of the Retrorectus or sublay mesh repair included two main steps; which is mesh placement deep to the recti muscles and mesh extension well beyond the hernia defect. The medial edge of each rectus muscle was identified by palpation, and the extreme medial edge of each rectus sheath was incised along its length to enter the submuscular space. This relatively bloodless plane could be created to the lateral edges of the rectus muscle on each side. Primary "peritoneal" closure was obtained using posterior rectus sheath above the arcuate line, the peritoneum itself, or excess sac below the arcuate line. The posterior rectus sheath along with the peritoneum is closed with zero proline sutures. Then mesh fascinated well beyond the around the defect (about at least 5 cm). The center point of the mesh was assigned by stitch to avoid mal-position of the mesh and edges of the mesh can be fixed to the posterior rectus sheath by multiple stitches. Organs within the abdomen are isolated from injury by the mesh by a layer of posterior rectus sheath and peritoneum. Adhesions to viscous are there by prevented. The edges of muscular sheath were sutured over the mesh by non-absorbable nylon suture [24-25].

B/Onlay Mesh Repair:-

The onlay repair was done with skin incision over the bulge or the defect. Using blunt dissection, both the rectus sheath and the defect containing the hernia contents were identified. The hernia sac was clearly dissected and the contents were dealt with and the margins of the defect were held by Kocher forceps. The sac was dealt with and its contents were reduced into the abdominal cavity. With non-absorbable suture, the defect in the linea Alba was closed and a proline mesh of adequate size was placed on the rectus sheath and fixed with stiches. Redivac suction drains were placed for all cases of two groups with mean time 5days and7days for sublay and onlay respectively and removed when drainage less than 20ml in 24 hours. All surgeries were done under general anesthesia and all the patients were given 1gm 3rd generation cephalosporin antibiotic preoperatively at the time of induction and continued till the 2nd postoperative day (1gm) daily. Data were analyzed using SPSS 18.0 software with, Fisher's exact test as appropriate; p <0.05 was considered to be statistically significant.

RESULTS:

A total of 120 patients of ventral hernias were managed by sublay mesh and onlay mesh repair. Youngest patient was 22 year old and oldest patient was 77year old, mean age of the patients was 48±5 years. According to the sex majority of the patients were female 90 patients which represent (75%) and male were (30) patients which represents (25%). According to the age group majority of the patients were between (51-60) years and were (40) patients whom represents (33.33 %) of all patients studied. The second age group was (41-50) years which constituted 25% of patients (i.e. about 58% or more than half of patients from age of (40-60) years as shown in a table (1).

Table (1): Age and gender distribution:

Age in years	Male No. 30	Female No. 90	Total	Percent
20-30	4	5	9	7.5%
31-40	8	12	20	16.66%
41-50	6	24	30	25%
51-60	8	32	40	33.33%
61-70	3	12	15	12.5%
71-80	1	5	6	5%
T0tal	30	90	120	100%

In our study most of hernias repaired were of a spontaneous type (60%) while that of incisional type were less and represent (40%) as noticed in table (2) and Figure (2).

Table (2): Type of hernia:

Post-operative complication	Sublay group n=60	Onlay group n=60	P value
Seroma	2(3.33%)	12 (20%)	<0.05
Wound infection	1 (1.66%)	6 (10%)	<0.05
Mesh removal	0 (0%)	1 (1.66%)	>0.05
Recurrence	0 (0%)	4 (6.66%)	<0.05
Flap necrosis	0 (0%)	1 (1.66%)	>0.05
Paralytic ileus	1(1.66%)	1(1.66%)	1.000

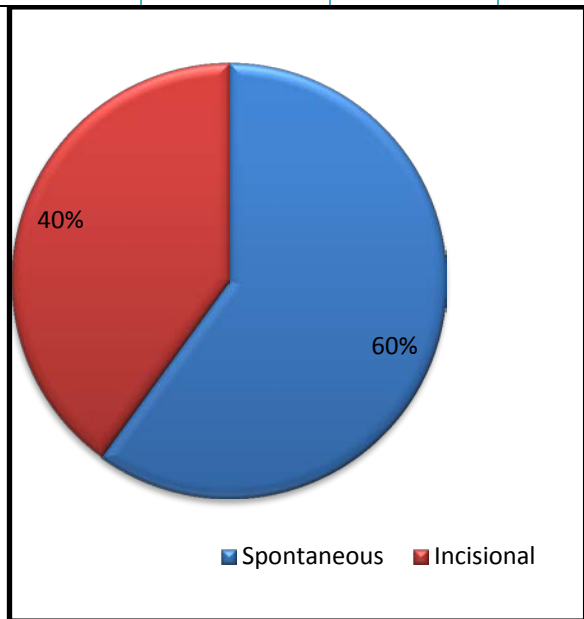


Figure (2) Distribution of Type of hernia.

Seroma formation was noticed in 2 patients (3.33%) in the sublay group while 12 patients (20%) of onlay group had same complication. Wound infection was seen in one patient (1.66%) in sublay technique group while in onlay group was (6) patients (10%).No septic mesh was removed in the sublay group while one patient (1.66%) of second group suffered from mesh infection and needed removal. Wound edge necrosis occur in one patient (1.66%) of onlay repair which was managed by excision of necrotic edge &

primary suturing and no case of flap edge necrosis occur in sublay group .Paralytic ileus as a complication was seen equally in both studied groups which was one patient(1.66%) in each group. Regarding recurrence in two year duration follow up in the sublay group there was no recurrence 0% while in onlay group recurrence rate was 4 patients (6.66%).

The tests of significance were assessed by p-value and we discovered that it is statistically significant in 3 results which are still the main problems in surgical management of hernias which were:-

- 1- Seroma
- 2- Wound infections
- 3- Recurrence rate

Otherwise there are no significant differences (statistically) in other variables studied as shown in table (3), figure (3).

Table (3): Post-operative complications:

Type of hernia	Number of patients	Percentage
Spontaneous	72	60%
Incisional	48	40%
Total	120	100%

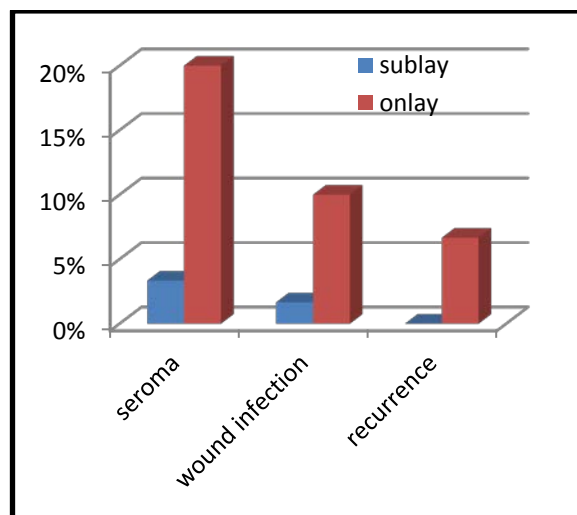


Figure (3) the most important statistically significant complications.

Mean duration of surgery and time of drain removal:

- 1- In sublay group the time was (68-112) minutes mean time 72 ±10 minutes and drain require (3-8) days for removal with an average5 ±2 days postoperatively.
- 2- In onlay group the time of surgery was (50-80) mean time 64 ±8 minutes and drain requires (5-14) days for drain removal with an average7±3 days postoperatively.

Table (4): Mean operative time of surgery.

Type of surgery	sublay	onlay	P value
Mean operative time	72 min	64 min	>0.05(N.S)

DISCUSSION:-

Ventral abdominal wall hernias are a common surgical problem encountered in clinical practice. The outcome of the surgery is based not only on the technique used but on the experience of the operator, meticulous dissection, tension free repair etc. [26]. Many methods are available to deal with these hernias. Common practiced techniques for hernial repair use mesh, which is placed either in a sublay or onlay position [27]. The refinement of the sublay technique decreased the recurrence rates and resulted in an overall better outcome making it to be declared the standard of care of ventral hernias. Primary tissue repair is associated with higher unacceptable recurrence rate. Nowadays tension free mesh repair is ideal hernia repair technique [28].

However, the optimal technique for mesh placement has not been established and remains controversial. The prosthetic mesh can be placed between the subcutaneous tissues of the abdominal wall and the anterior rectus sheath (onlay mesh repair) as well as in the preperitoneal or retromuscular (sublay mesh repair). The latter technique has several advantages one of being not transmitting the infection from subcutaneous tissues down to the mesh as it lies quite[29]. Increased intra-abdominal pressure acting anteriorly on the margins tends to oppose the mesh to the abdominal wall rather than distracting it. Some studies suggest that the use of the sublay technique as a treatment option for ventral hernias appears to be less complicated than the onlay technique [30, 31, 32].

Mean duration of surgery in our study, in cases that underwent onlay mesh repair was 64 min, while in cases with sublay Mesh repair took more time and the duration of surgery was 72 min in present series where P value>0.05 which is not significant. The difference could be accounted to more time required for dissection to create retromuscular space. Securing adequate hemostasis is another burden on time. Ease of operation was largely subjective and depends on surgeons' experience, exposure, quality of assistance, and conductive facilities. Furat Shani reported a mean duration of 64 min for onlay and a mean duration of 88 min for sublay mesh repair [30], while in Aly Saber series the mean duration for onlay and sublay mesh repair were 67.5 and 100 min, respectively [31]. And Kharde K et al in their study noted that the operative time for sublay mesh repair was (77.8 min) which was more than that required for onlay mesh repair (69.8 min) [32] (who study a comparative of onlay and retrorectus mesh placement in incisional hernial repair)

The most common complication observed in our study was seroma 2(3.33%) & 12(20%) in sublay and onlay respectively. This complication was managed by repeated

aspiration and by tube drain in some cases. Onlay technique had more of seroma formation, due to the fact that onlay techniques require significant subcutaneous dissection to place the mesh, which can lead to devitalized tissue with seroma formation or infection so we use in our study only subcutaneous drain and don't need to insert retromuscular drain because there was less dead space, little fat high lymphatic which decrease incidence of seroma formation although some studies used subcutaneous and retromuscular drains. The superficial location of the mesh also puts it in danger of becoming infected if there is a superficial wound infection. Wound infection was 1(1.66%) & 6(10%) in sublay and onlay respectively. These patients were treated with appropriate antibiotics and regular dressing. Patients required removal of mesh was 1(1.66%) in onlay group because the infection was deep and not responding well to antibiotics while there is no mesh removed in sublay group. Furat Shani found seroma 12% & 1% in onlay and sublay respectively, Aly Saber found seroma 6% & 2% in onlay and sublay respectively and Kharde K et al in his study found seroma 16% & 12% in onlay and sublay respectively.

No recurrence of hernia was noticed in sublay mesh repair in our study where as in the onlay group recurrence occurred in 4 (6.66%) cases (P < 0.05). Aly Saber found a recurrence rate to be 8% in onlay and 3% in sublay mesh repair. Furat Shani found a recurrence rate to be 1% in onlay and no recurrence in sublay mesh repairs and Kharde K et al in his study found recurrence rate to be 4% in onlay and no recurrence in sublay mesh repair.

A retrospective study in Europe done by de Vries Reilingh et al noticed a recurrence rate of 23% in cases that underwent onlay mesh repair, and no recurrence in patients with pre-peritoneal or sublay mesh repair[33].

Sublay mesh repair is considered superior because the mesh with significant overlap placed under the muscular abdominal wall works according to Pascal's principles of hydrostatics. The intra-abdominal cavity functions as a cylinder, and, therefore, the pressure is distributed uniformly to all aspects of the system. Consequently, the same forces that are attempting to push the mesh through hernia defects are also holding the mesh in place against the intact abdominal wall. In this manner, the prosthetic mesh is held firmly in place by intra-abdominal pressure. The mechanical strength of the prosthetic mesh prevents protrusion of the peritoneal cavity through the hernia because the hernial sac is indistensible against the mesh. Over time, the prosthetic mesh is incorporated into the fascia and unites the abdominal wall, now without an area of weakness.

Table (5): Comparison with other study.

	Kharde K		Furat Shani		Aly Saber		Our study	
	Olay	Sublay	Onlay	Sublay	Onlay	Sublay	Onlay	Sublay
No. of patient	25	25	52	50	100	100	60	60
Time of operation	(69.8) min	(77.8)min	(64) min	(88) min	(67.5)min	(100)min	(64) min	(72) min
Seroma	16%	12%	12%	1%	6%	2%	20%	3.33%
Wound infection	4%	0%	2%	1%	8%	4%	10%	1.66%
Recurrence	4%	0%	1%	0%	8%	3%	6.66%	0%

CONCLUSIONS:

1. Sublay mesh hernioplasty is a better alternative to onlay mesh hernioplasty for all forms of ventral hernia cases.
2. Minimal complications and better outcome with sublay mesh hernioplasty in comparison to onlay.

RECOMMENDATIONS:

- 1- Because of low complications regarding infection, seroma formation and low recurrence rate in sublay mesh repair during 2 years follow up in which most of the recurrence will happen, we encourage using this method for repair of ventral hernias.
- 2- We recommend increasing the number of the study group and prolongation of follow up time to have much more solid results.

REFERENCES:

1. Rucinsb J, Margolit M, Panagopoukw G, et al. Closure of the abdominal midKnc fascia: Meta-analysis delineates the optimal tecfamqw. *Am J«JJ67:42I-426, 2001.*
2. Muysoms FE, Antoniou SA, Bury K, et al: European Hernia Society guidelines on the closure of abdominal wallincisions. *Hernia 19:1-24, 2015.*
3. Carlson MA, Ludwig KA, Condon RE: Ventral hernia and other complications of 1.000 midline incisions. *South MedJ 88:450-453,1995-*
4. Seiler CM, Deckert A, Diener MK, et al Midline versus transverse incision in major abdominal surgery: A randomized, double-blind equivalence trial (POVATI: ISRCTN60734227). *Ann Surg 249313-920, 200938.*
5. Luijendijk RW, Hop WC, van den To! MP, et al: A compari-son of suture repair with mesh repair for incisional hernia. *.V Eng!J Med 343:392-398, 2000..*
6. Greenall MJ, Evans M, Pollock AV. Midline or transverse laparotomy? A random controlled clinical trial. Part I: Influence on healing. *Br J Surg1980; 67:188-90.*
7. Condon RE. Incisional hernia. In: Nyhus LM, Condon RE, editors. *Hernia*. 3rd ed. Philadelphia, Pennsylvania: Lippincott; 1995. p. 319-36.
8. Steve EW. Hernia. In: Townsted CM, editor. *Sabiston Textbook of Surgery*. 16th ed. Singapore: Harcourt Publishers; 2001. p. 783-801.
9. Fitzgibbons RJ, Greenburg AG, editors. *Nyhus and Condon's Hernia*. 5th ed. Philadelphia: Lippincott, Williams and Wilkins; 2002.
10. Wantz GE. Abdominal wall hernias. In: Schwartz SI, Shires GT, editors. *Principles of Surgery*. 6th Ed. New York: McGraw Hill; 1994. p. 1517-44.
11. Le HuuNho R, Mege D, Ouaiissi M, Sielezneff I, Sastre B. Incidence and prevention of ventral incisional hernia. *J Visc Surg. 2012; 149:e3-14.*
12. Guerra O, Maclin MM. Non-crosslinked porcine- derived acellular dermal matrix for the management of complex ventral abdominal wall hernias: a report of 45 cases. *Hernia. 2014; 18:71-9.*
13. East, JM. Mesh Tuck Repair of Ventral Hernias of the Abdomen: A New, Simplified Technique for Sublay Herniorrhaphy. *West Indian Med Journal. 2007; 56 (6): 514-519.*
14. Bessa SS, El-Gendi AM, Ghazal AH, Al-Fayoumi TA. Comparison between the shortterm results of onlay and sublay mesh placement in the management of uncomplicated paraumbilical hernia: a prospective randomized study. *Hernia. 2015; 19:141-6.*
15. Agbakwuru E, Olabanji J, Alatise O, Okwerekwu R, Esimai O. Incisional hernia in women: Predisposing factors and management where mesh is not readily available. *Libyan J Med. 2009; 4:66-9.*
16. Holihan JL, Nguyen DH, Nguyen MT, Mo J, Kao LS, Liang MK. Mesh location in open ventral hernia repair: A systematic review and network meta-analysis. *World J Surg. 2016; 40(1):89-99.*
17. Stoppa RE. The treatment of complicated groin and incisional hernias. *World J Surg 1999; 13:545-54.*
18. Rives J. Major incisional hernia. In: chewal JP (ed) *Surgery of the abdominal wall*. Springer Paris 2000; 116-44.
19. Wantz GE. Incisional hernioplasty with Mersilene. *SurgGynaecolObstet 2001; 172: 129-37. QMJ VOL.9 No.16 216.*
20. Berry MF, Paisley S,LowWD.Repair of large complex recurrent incisonalhernias with retromuscular mesh and panniculectomy *Am J Surg 2007;194:199-204.*
21. CW, Pham TH, Joseph A et al. Long term outcome of 254 complexincisional hernia repairs using modified Rives-Stoppa technique *World J Surg2007; 31: 2398-2404.*
22. Martin- Duce A, Noguerales F, Villet AR etal.Modifications to Rives technique for midline incisional hernia repair. *Hernia 2001; 5: 70-72.*
23. Langer C, Schaper A, Liersch T et al. Prognosis factors in incisional hernia surgery: 25 years of experience. *Hernia 2005; 9: 16-21.*
24. Duce AM, Muguerza JM, Villeta R (1997) The Rives operation for the repair of incisional hernias. *Hernia 1:175-177`*
25. Klinge U, Conze J, Krones C, et al. (2005) Incisional hernia: opentechniques. *World J Surg 29:1066-1072*
26. Chien, J.S., Tsai, P.J, Liu, K.Y, Wang, S., Shyr, Y.M, Su, C.H., and Chen, TH. Open Suture Repair and Open Onlay Technique for Incisional Hernia in Elderly Patients with Multiple Comorbidities. *International Journal of Applied Science and Technology. 2011; 1(3): 34-40.*
27. Stey AM, Russell MM, Sugar CA, Hall BL, Zingmond DS, Lawson EH, et al. extending the value of the National Surgical Quality Improvement Program claims dataset to study long-term outcomes: Rate of repeat ventral hernioplasty. *Surgery.2015; 157:1157-65.*
28. MehmudAuranga 12.Korenkow M, Sauerland S, Arndt M, BogradL,Neugebauer EAM, Troidl H. Randomized Clinical trials of suture repair.polypropylene mesh or autodermal hernioplasty for incisional hernia. *Br J Surg 2002; 89: 50-6.*
29. SirramBhat M, Hernia, SRB's Manual of surgery, 4th edition, 2013(18):827.
30. Furat Shani Aoda, Alaa Sharif Ibrahim. Sublay versus onlay mesh repair of ventral hernia. *QMJ.ISSN:18170153VOLUME:9 ISSUE. 2013 pages 208-216.*
31. Aly Saber, Emad K. Bayumi. Onlay versus Sublay Mesh Repair for Ventral Hernia. *Journal of Surgery. Special Issue: Abdominal Surgery; Toward the Best. Vol.4, No 1-1, 2015, pp. 1-4.*
32. Kharde K, Dogra BB, Panchabhais S, Rana KV, Sridharan S, Kalyan S. A comparative study of onlay and retrorectus mesh placement in incisional hernia repair. *Med J DY PatilUniv 2013; 6:258-62.*
33. de Vries Reilingh TS, van Geldere D, Langenhorst B, de Jong D, van der Wilt GJ, van Goor H, et al. Repair of large midline incisional hernias with polypropylene mesh: Comparison of three operative techniques. *Hernia 2004;8:56-9*