

Elongated Styloid Process

Hussain Saheb S¹, Muralidhar P Shepur², S.D Desai³, S.T Thomas⁴, Haseena S⁵

^{1,5} Research Scholars in BLDE University's BM Patil Medical college, Bijapur, Karnataka

³ Professor & Head of Anatomy, BM Patil Medical College, Bijapur, Karnataka.

^{1,2,4} Assistant Professors, Department of Anatomy, JJM Medical College, Davangere, Karnataka, Pin – 577004.

Abstract

The styloid process is a cylindrical, long osseous cartilaginous process located on the petrous part of temporal bone. Normal length of it usually 20-25 mm. The apex of it is connected with the lesser cornu of hyoid bone ipsilaterally through stylohyoid ligament. In the view of development stylohyoid ligament is the continuation of the styloid process apex, developed from second branchial arch. In present article we reported two skulls with bilateral elongated styloid process. In the first skull length of styloid process is 8.2cm on right and 5cm on left. In other skull 6.4cm on right and 5.2cm on left.

INTRODUCTION

The styloid process is extension of osseous process from the posterior lower surface of the petrous part of temporal bone located anteriorly to stylomastoid foramen. The direction of process is downwards and slightly inside. It is developed from second branchial arch [1]. The normal length of styloid process is 20-25mm, between apex of process and lesser cornu of hyoid bone there is attachment called as stylohyoid ligament. The tip of the process is situated laterally from the pharyngeal wall and immediately behind the tonsillar fossa and critically between the internal and external carotid arteries and has attachment of three muscles and two ligaments. Rarely stylohyoid ligament ossifies and increase the length of styloid process and called as elongated styloid process when it is longer than 30mm[2].

Clinically the relation of tip of the stylohyoid process is important, course of it situated in between external and internal carotid arteries, anteriomedially it is related to facial nerve, medially with accessory and vagus nerves. The one of the symptoms in Eagle's syndrome is approximation of the glossopharyngeal nerve with the styloid ligament. The causes for the elongated styloid process or Eagle's syndrome are the persistent angulation of the Reichert's cartilage and its neurovascular relationships, styloid ligament ossification, osseous tissue growth at the insertion of the styloid ligament. The more common symptoms of this syndrome are dysphasia, headache, ipsilateral otalgia, foreign body sensation, neck pain during rotation, facial, carotid and throat pain [3, 4, 5].

CASE REPORT

In routine osteology demonstration we have found out two dry adult skulls with the elongated styloid process. In the first skull right styloid process was 8.2cm long and 1.2 cm thick at the base which is extremely rare. The styloid process proper is 5.1cm long and remaining 3.1cm was ossified styloid ligament the junction between the two was marked by bulge of bony mass. The stylohyoid part broken was on the left side and it was 5cm long and 1cm thick at base (Figure 1. B). In second skull on the right side it was 6.4cm and 0.6cm thick at base and it was in two segments, on left side it was in only segment with 5.2cm length and 0.5cm thick at base(Figure 1. A).

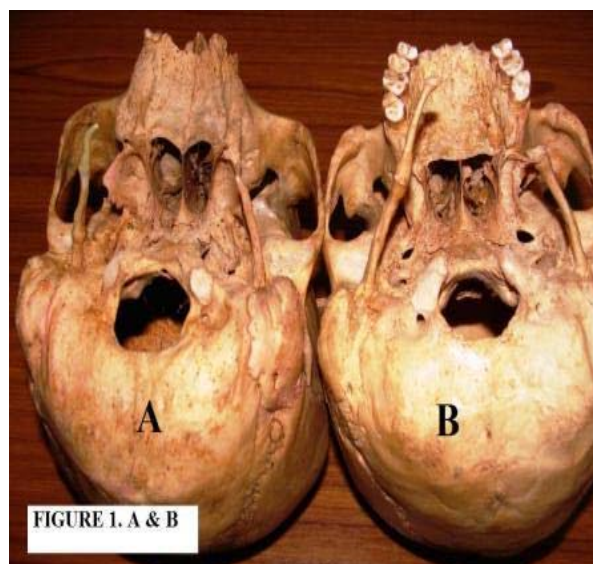


Figure 1. The Skull (A&B) showing elongated styloid process

DISCUSSION

The lower part of petrous bone giving origin for a slender bony projection called as styloid process. Richert's cartilage of second branchial arch gives rise this process and persists as a stylohyoid ligament between lesser cornu of the hyoid and tip of the styloid process passing between external and internal carotid arteries, the glossopharyngeal and vagus nerves are adjacent to it[6].

A surgeon from Padua Pietro Marchetti was observed on ossifying process of stylohyoid ligament to an elongation of the styloid process in 1652. The symptoms of elongated styloid process were described by Weinlecher in 1872. In 1937 and 1949 Eagle described fully about elongated styloid process or Eagle's syndrome in his study in ear-nose-throat patients and dentomaxillofacial cases. Eagle stated that elongated styloid process term can use only when the length of process is more than 30mm or when there is stylohyoid ligament ossification [7]. Elongated styloid process can cause cervical and pharyngeal pain on swallowing, opening of the mouth, speaking, and sensation of a foreign body in the oropharynx, during movement of the cervical region and pain radiating to the ear [6, 8]. It may cause stroke due to the compression of carotid arteries [9, 10, 11]. The compression depends on the size, shape and orientation of the ossified styloid process [12].

Various theories were proposed by Steinmann to explain ossification of styloid process, These were: "Theory of reactive hyperplasia" – trauma can cause ossification at the end of the styloid process, down the length of the styloid ligament, since the styloid ligament contains remnants of its connective tissue and fibro cartilaginous origins, the potential for ossification remains; "Theory of reactive metaplasia" – an abnormal post-traumatic healing response initiates the ossification of stylohyoid ligament; and "Theory of anatomic variance" – the early elongation of the styloid process and ossification of the styloid ligament are anatomical variations that occur without recognisable trauma[13].

Eagle classified the syndrome in to two types, the first one is classic type and second one is carotid artery type, the classic type develops by

fibrous tissue formation in the area of a calcified stylohyoid complex, distorting the cranial nerve endings in the tonsillar fossa following surgical removal of tonsil, the second type is not dependent upon tonsillectomy is called as stylocarotid syndrome or carotid artery syndrome. The main complaint of elongated process patients is cervical pain while turning head because elongated styloid process passes between external and internal carotid arteries and accompanying nerve plexuses [14].

Keur et al proposed that if the length of styloid process is more than 30mm then it is elongated [15]. Jung et al stated that it should be consider as elongated when it is more than 45mm [16]. Lindeman suggest that the length of styled process is variable individually, he defined elongated when it is more than 40mm [17].

Diagnosis of elongated styloid process can be made by digital palpation of the styloid process in the tonsillar fossa which produces the pain. It can be diagnosed by radiographic and CT scan also, by internal or external approach styloid process can be shortend [18]. The knowledge of elongated styloid process can help otolaryngologist in surgeries of that particular area.

REFERENCES

1. Standing S: Skull and Mandible. In Gray's Anatomy. The Anatomical basis of clinical practice. 39th edition. Elsevier, Edinburg; 2005:470p.
2. Monsour PA, Yougn WG. Variability of the styloid process and stylohyoid ligament in panoramic radio- graphs. Oral Surg Oral Med Oral Pathol. 1986; 61:522-526.
3. Eagle WW: The symptoms, diagnosis, and treatment of elongated styloid process. Am Surgery 1962; 28:1-5.
4. Eagle WW. Elongated styloid process. Arch otolaryngeal 1948; 47:630-40.
5. Murtagh RD, Caracciolo JT, Fernandez G. CT findings associated with Eagle Syndrome. Am J Neuroradiol. 2001; 22: 1401–1412.
6. Rechtweg JS, Wax MK. Eagle's Syndrome: A Review. Am J Otolatngol 1998;19:316–21.
7. De Souza Carvalho AC, Magro Filho O, Garcia IR Jr, de Holanda ME, de Menezes JM Jr. Intraoral approach for surgical treatment of Eagle syndrome. Br J Oral Maxillofacial Surg 2009; 47:153–4.
8. Prasad KC, Kamath MP, Reddy KJ, Raju K, Agarwal S.. Elongated styloid process (Eagle's Syndrome): A clinical study. J Oral Maxillofacial Surg 2002; 60:171–5.

9. Carter L. Soft tissue ossification and ossification. In: White SC, Pharoah MJ, editors. *Oral Radiology, Principles and interpretation*. Missouri: Mosby. 2004.597-614.
10. Prasad KC, Kamath MP, Reddy KJ, Raju K, Agarwal S. Elongated styloid process (Eagle's syndrome): a clinical study. *J Oral Maxillofac Surg*. 2002; 60:171–175.
11. Chuang WC, Short JH, McKinney AM, Anker L, Knoll B, McKinney ZJ. Reversible left hemispheric ischemia secondary to carotid compression in Eagle syndrome: surgical and CT angiographic correlation. *Am J Neuroradiol*. 2007; 28:143–145.
12. Ramadan SU, Gokharman D, Tuncbilek I, Kacar M, Kosar P, Kosar U. Assessment of the stylohyoid chain by 3D-CT. *Surg Radiol Anat*. 2007;29:583–588.
13. Steinmann EP. Styloid syndrome in absence of an elongated process. *Acta Otolaryngology* 1968; 66:347-56.
14. Eagle W. Elongated styloid process: Report of two cases. *Arch Otolaryngology* 1937; 25:584–7.
15. Keur JJ, Campbell JP, McCarthy JF, Ralph WJ. The clinical significance of the elongated styloid process. *Oral Surg Oral Med Oral Pathol* 1986; 61:399-404.
16. Jung T, Tschernitschek H, Hippen H, and Schneider B, Borchers L. Elongated styloid process: when is it really elongated? *Dentomaxillofac Radiol* 2004; 33:119-24.
17. Lindeman P. The elongated styloid process as a cause of throat discomfort. *J Laryngol Otol* 1985; 99: 500–8.
18. Balbuena L Jr, Hayes D, Ramirez SG, Johnson R. Eagle's syndrome (elongated styloid process). *South Med J* 1997; 90:331-4. Comment in: *South Med J* 1998; 91:43.