

Accessory Optic Canal in South Indian Dry Skull

Sweta.V.R, Dr.S.Saravana Kumar,
Saveetha Dental College,
Chennai

Abstract:

The presence of the double optic canal is a rare phenomenon. 67 human cranial cavities of unknown age and sex were collected from the Department of Anatomy, Saveetha Dental College. During morphological study of these cranial cavities, 3 cranial cavities showed duplication of the optic canal. One cranial cavity showed bilateral duplication whereas the other two had unilateral duplication. The main canal was in the usual position but the accessory canal was located inferomedial to it. Whenever there is presence of double optic canal, the larger foramen transmits the optic nerve and the smaller foramen transmits the ophthalmic artery. It is important to know the significance of the double optic canal during interventional procedures of optic canal and surrounding regions especially during endoscopic tumor removal and optic nerve decompression.

Key Words: Bilateral , Unilateral, duplication, optic canal, cranial cavity.

INTRODUCTION:

The optic canal connects the middle cranial fossa to the apex of the orbit and it is formed by the two roots of the lesser wing of the sphenoid. It is traversed by the optic nerve and its meningeal coverings, the ophthalmic artery and by the branches from the periarterial sympathetic plexuses. In the optic canals the optic nerve lies medial to the Ophthalmic artery. Duplication of the optic canal is very rare anomaly [1-3] This anomaly is seen in both sexes at various ages and in a number of races [4]. This anomaly is ascribed to ossification process of duramater between the optic nerve and ophthalmic artery as the inferior small canal is occupied by ophthalmic artery [5]. Duplications of optic canals have been reported earlier by Warwick [1], Choudhary et al [2], and Mandavi Singh [6]. In these cases it is seen that the main canal carries the optic nerve whereas the accessory canal carries the ophthalmic artery.

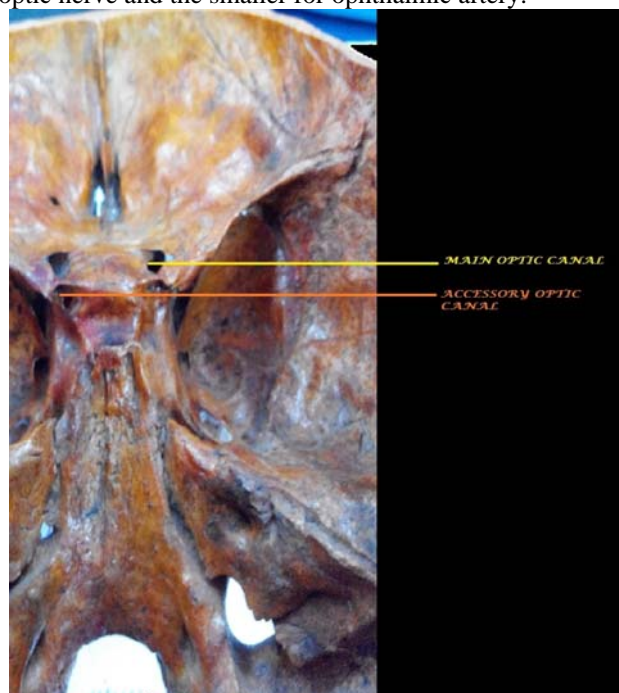
MATERIALS AND METHODS:

Materials for this study included 67 cranial cavities. Three dry adult human skulls showed duplication of the optic canal. One of which showed bilateral duplication and the other two unilateral duplication. These consist of main canal which is in usual position. The other canal known as accessory canal was inferomedial to it in position. The length was measured along the medial wall of main canal. Cranial as well as orbital ends of the both canals were studied for shape and direction. It was difficult to measure the length and thickness of septum separating the double optic canal due to unapproachability of the region. The direction of the main canal was posteromedial and upward. Accessory canal was parallel to the main canal. The orbital openings of both canals were rounded and obliquely placed. The cranial opening of both canals were rounded and medially oriented. The septa between the two canals was very thin. The skull under study showed no tendency for excessive bone formation.

DISCUSSION:

Various authors have previously recorded cases of duplicate optic canals during the late 19th and early 20th century. Out of these cases only very few are of bilateral

type. Presence of double optic canals is seen both in male and female skulls and in all age groups by different authors. Visconti(1885) observed bilateral duplication in one of the two skulls that had double optic canal. Zoja(1885)[7] reported five cases out of which one was bilateral(female) and the rest were unilateral(male). Le Double (1903)[4] also reported only one case of bilateral duplication(male). Similarly, in recent studies Choudhry, Choudry and Anand reported double optic canals in three skulls- two bilaterally duplicated and one unilaterally duplicated. Embryological basis for the formation of double optic canal is not clear. It may be considered to be due to ossification of the duramater covering the optic nerve dividing the optic canal into two. Another cause of development is ossification of fibrous tissue between the duramater covering the optic nerve and ophthalmic artery [8]. Some speculated that a small projection appear in formation of groove in the floor of the optic canal.[9] This bony canal when large can result in division of canal into two parts, the upper and larger for optic nerve and the smaller for ophthalmic artery.



RESULT:

Out of the 67 cranial cavities examined, 3 cranial cavities possessed double optic canal(4.47%). The duplication was bilateral in one skull (1.49%) and unilateral in the other two (2.98%). In all these cases the main canal was in its usual position and the accessory canal inferomedial to it. The length of the canal was between 7-10 mm. The size of the canal was 5-8mm transversely and 4-7 mm vertically. The main canal and accessory canals were placed parallel to each other. The thickness of the septa separating the two canals were found to vary in each of the cases.

DEVELOPMENT OF OPTIC CANAL:

The optic canal is formed in the lesser wing of sphenoid. The ossification centre for the lesser wing of sphenoid is at the ala orbitalis cartilage. This takes place at about 12 fetal weeks. From 12th to 16th week the two centres formed on the superior and lateral side rapidly fuse and thus by the 16th week the optic foramen is almost completely covered by bone. The inferolateral border is formed by the fusion of the antero inferior segment of the optic strut from the lesser wing of sphenoid along with the postsphenoid center of the body of sphenoid. The optic foramen thus formed resembles a key hole at this stage. The formation of optic canal follows this process and this takes place during the 5th month of foetal life. During this stage the second strut joins the lesser wing of sphenoid. At this stage the ophthalmic artery takes up the superior position. The formation of double optic canal or duplicated optic canal takes place when the second strut develops above the ophthalmic artery instead of below it. So, the optic nerve occupies a separate foramen.[10].This, is hence, known as double optic canal.

THEORIES PUT FORTH AS TO THE REASON BEHIND THE FORMATION OF DOUBLE OPTIC CANAL:

1. Le Double speculated that the ossification of dura which covers the optic nerve, divides the optic canal [4].
2. Augier suggested that the duplication represents the persistence of a foramen, "le trou metoptique", due to the presence of an aberrant ophthalmic vein [1].
3. Keyes JEL postulated that the bony projection in the infero lateral wall of the optic canal, when it is large, divides the optic canal [8].
4. Wolff E, is of the opinion that the fibrous tissue which separates the optic nerve and the ophthalmic artery ossifies and divides the canal [11].
5. The duplications of optic canal are developmental in origin and they result from the anomalous growth of the optic strut. The latter anomaly is not due to dural ossification [12].

CONCLUSION:

The knowledge regarding the presence of double optic canal is useful in performing the surgical exploration of the optic canal during tumour removal and decompression, or while approaching the cavernous sinus or the sella. The knowledge of the course of the ophthalmic artery is required to make the optic canal explorations safer. The use of preoperative angiography for this purpose is highly recommended [13]. Errors in detecting the anomalies of the optic canal can occur, by mistaking it for clinoid process pneumatization, posterior ethmoid air cell, carotico clinoid foramen and a defect in the greater wing of the sphenoid or in an ectopic sphenoid cellule.[14] The variations in the optic canal can pose a threat during endoscopic optic nerve decompression and during sphenoid ethmoid injuries and they can also create confusion during the interpretation and the evaluation of the CT scans or the X-rays of the sphenoid ethmoid region.

REFERENCES:

- [1] Warwick R, A juvenile skull exhibiting duplication of optic canal and division of superior orbital fissure. *J Anat* 1951; 85:289-91
- [2,3] Choudhary R, Choudhary S, Anand C. Duplication of optic canals in human skulls. *J. Anat.* 1988; 159:113-116.
- [4] Le-Double AF, *Traite des variations des os du crane de l'homme* paris vogot freres 1935; 1903:372.
- [5] White LE An anatomic and x-ray study of optic canal *Boston Med surg J* 1942; 189:741-48.
- [6] Singh M. Duplication of optic canal in adult Japanese human skulls. *J Anat Soc India.* 2005; 54(2): 1-9.
- [7] Zoja.G (1885) Spora il foro ottico doppio. *Bolletino scientifico, pavia*, 7,65-69.
- [8] Keyes JEL Observations on four hundred optic foramina V. Graefe's. *Arch. Opthtal.* 1935;13:538-68
- [9] Dr. Stephen Dayal, Dr. Manjunath KY in duplication of optic canals
- [10] Scheuer I, Blacks, Christie A, *Developmental juvenile osteology in head, neck and dentition*, Elsevier 2000 pp 90
- [11] Wolff E. *Anatomy of the Eye and orbit*. 7th ed, vol 15, London: H.K. Lewis, 1976.
- [12] Leon K E. Embryology of normal optic canal and its anomalies an anatomic and roentgenographic study. *Investigative Radiology.* 1996; 1(5):346-362.
- [13] Slavin K V, Dujovny M, Soeira G, Ausman J. Optic canal-Microanatomic study. *Skull Base surgery* 1994; 4(3):136-44.
- [14] Dr. Girish V. Patil, Dr. Sanjeev Kolagi, Dr. Padmavathi G., Dr. G.B. Rairam, duplication of optic canals in human skulls.