

Variations of Posterior Condylar Canal in South Indian Skulls

Manoj Kumar

*BDS 1st year, Department Of Anatomy,
Saveetha Dental College,
Chennai-77*

Abstract:

Aim:

To assess prevalence, normal anatomic patterns and variations of the posterior condylar canal and in foramina of skull have importance for their correct identification as normal or abnormal .

Materials And Methods :

60 skulls were examined by direct observation from the Department of anatomy, Saveetha dental college ,chennai ,Tamilnadu, India . For the unilateral or bilateral presence or absence of the canal and for the presence of multiple canals or any other variations.

Results :

Of 60 skulls we have seen 11 skulls with unilateral presence of canal in left side with an incidence of 18.33%, and right side in 9 skulls with an incidence of 15%. The bilateral presence of posterior condylar canal is seen in 29 skulls with an incidence of 48.33%. The canal is absent in 10 skulls with an incidence of 16.66%.

Conclusion :

The condylar veins can be used as access routes to hypoglossal dural arterio venous fistulas .Anatomical variations of the posterior condylar canal are important during the treatment of dural arteriovenous fistula. Our study gives basic knowledge to the clinicians and surgeons before planning a surgery in the occipital condylar region.

Keywords : Condylar emissary vein, posterior condylar canal, occipital bone, unilateral , bilateral.

INTRODUCTION:

The posterior condylar canal is the largest emissary foramen of the posterior cranial fossa. It is apparent just postero inferior to the jugular foramen and posterior to the hypoglossal canal(1). The condylar canal gives way to a condylar emissary vein from sigmoid sinus to vertebral vein. Posterior condylar canal also transmits meningeal branches of the occipital artery . The condylar canal gives way to a condylar emissary vein from sigmoid sinus to vertebral vein between the axis and atlas, in most cases(1) or between the superior bulb of the internal jugular vein and suboccipital venous plexus (8,9,10). The posterior condylar foramina is the largest of the emissary foramina present in the human skull (13). The foramina opens into the posterior condylar canal which is present in a depression immediately posterior to the occipital condyle. It may persist in majority of the adult skulls. Variations in posterior condylar canal may be associated with variations in posterior condylar vein which may be wrongly considered as pathological. It also transmits the meningeal branch of occipital artery (14). An enlarged posterior condylar emissary vein may be one of the causes for pulsatile tinnitus (12). So this study was planned to assess prevalence, normal anatomic patterns and variations of the condylar canal(2).

MATERIALS AND METHODS:

This study was carried out on 60 dry human skulls from Department of Anatomy , Saveetha dental college, Chennai, Tamilnadu ,India. The skulls were observed for presence or absence of posterior condylar canals and for the presence of multiple canals or any other variations. we observed all 60 skulls for presence of unilateral and

bilateral presence through direct vision and tabulated according to its incidence.

Table 1: Percentage of incidence:

Unilateral left	18.33%
Unilateral right	15%
Bilateral presence	48.33%
Absence	16.66%

RESULT:

Of 60 skulls we have seen 11 skulls with unilateral presence of canal in left side with an incidence of 18.33%, and right side in 9 skulls with an incidence of 15%. The bilateral presence of posterior condylar canal is seen in 29 skulls with an incidence of 48.33%. The canal is absent in 10 skulls with an incidence of 16.66%.

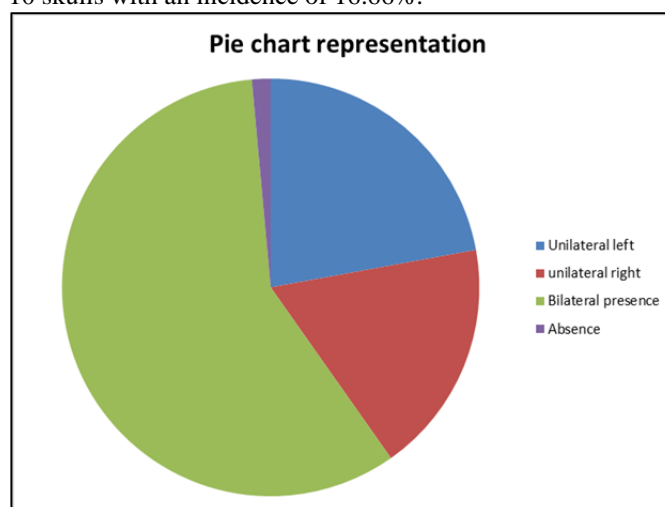


Fig 1: Percentage in pie chart:

DISCUSSION:

Posterior condylar canal opens at the groove for sigmoid sinus, posterolateral to jugular foramen in the posterior cranial fossa. These anomalous foramina also opens in posterior cranial fossa(3). This leads to speculation that these anomalous foramina might be acting as an additional source of drainage of intracranial veins into extra cranial veins. Ginsberg observed that the posterior condylar to be bilateral in 55.9% and unilateral in 17.6%(4). Boyd found the posterior condylar canal with an incidence of 77% unilateral(5). Krause discovered that condylar canal was present bilaterally in 21% and unilaterally in 38% of skulls(6). Berge & Bergman(11) found that the posterior condylar canal was doubled in six of the 144 patent foramina (4%) and tripled in one case (<1%). In our study we have found posterior condylar canal present unilaterally in left side in 11 of 60 skulls with an incidence of 18.33% and right side in 9 of 60 skulls with an incidence of 15%. The bilateral presence of posterior condylar canal is seen in 29 of 60 skulls with an incidence of 48.33%. The canal is absent in 10 out of 60 skulls with an incidence of 16.66%.

CONCLUSION :

The condylar veins can be used as access routes to hypoglossal dural arterio venous fistulas .Anatomical variations of the posterior condylar canal are important during the treatment of dural arterio venous fistula. Our study gives basic knowledge to the clinicians and surgeons before planning a surgery in the occipital condylar region.

REFERENCE:

- 1) Krause W. The posterior condylar canal. In Testut, L. & Latarjet, A. *Treaty human anatomy*. Barcelona, Salvat, 1988. V.1 152-8.
- 2) Lanzieri CF; Duchesneau PM, Rosenbloom SA; Smith AS & Rosenbaum, AE The significance of asymmetry of the foramen of Vesalius.
- 3) Hollinshead WH, Rosse C. *Textbook of Anatomy*, 4th edn. New York, NY/Philadelphia, PA: Harper and Row, 1985. p871.
- 4) Ginsberg LE. The posterior condylar canal. *AJNR Am J Neuroradiol*. 1994;15(5):969-72.
- 5) Boyd GI. The emissary foramina of the cranium in man and the anthropoids. *J Anat*. 1930;65(Pt1):108-21.
- 6) Krause W. The posterior condylar canal. In: Testut L, Latarjet A, eds. *Treaty of Human Anatomy*. Barcelona, Spain: Salvat; 1988. Vol1. pp.152-8.
- 7) Kiyosue H, Hori Y, Okahara M. Dural arteriovenous fistula involving the hypoglossal canal: case reports and literature review. *8th World Federation of Interventional and Therapeutic Neuroradiology. Interv Neuroradiol*. 2005;11(Suppl2):127.
- 8) Coin MCG, Foramen M. In: Newton TH & Potts DG. *Radiology of the skull and brain: the skull*. St. Louis, Mosby, 1971. V. 1 275-86.
- 9) Hacker H. Normal supratentorial veins and dural sinuses. In: Newton TH & Potts DG. *Radiology of the skull and brain: the skull*. St. Louis, Mosby, 1971. V. 2. 1851-77.
- 10) Williams PL, Warwick R, Dyson M, Bannister, L. *Gray's Anatomy* 37ed. New York, Churchill Livingstone, 286-7, 1989.
- 11) Berge JK.; Bergman RA. Variations in size and in symmetry of foramina of the human skull. *Clin. Anat*. 6:406-13, 2001.
- 12) Lambert PR, Robert W. Objective tinnitus in association with an abnormal posterior condylar emissary vein. *The American journal of otology*, May 1986; 07(03): 204-207.
- 13) Boyd GI. The emissary foramina of the cranium in man and the anthropoids. *J of Anat* 1930; 65:108121
- 14) Kiyosue H, Okahara M, Sagara Y, Tanoue S, Ueda S, Mimata C. Dural arteriovenous fistula involving the posterior condylar canal. *Am J Neuroradiol* 2007; 28:1599-601.