

Study of Occurance of Metopic Suture in Adult South Indian Skulls

Ajrish George S^[1], Ms.Thenmozhi^[2]

^[1]First Year BDS, ^[2]HOD, Department Of Anatomy
Saveetha Dental College, No:162 Poothamalle High Road, Chennai-77.

Abstract :

Aims & Objective

To study the presence of metopic suture in adult skulls

Background

The metopic suture is a dense connective tissue structure that divides the two halves of the frontal bone of the skull in infants and children. It usually disappears by age of six years with the two halves of the frontal bone being fused together. If it is not present at birth then both the frontal bone would be fused (craniosynostosis) which will cause keel-shaped deformity of skull called Trigonocephaly.

It has been observed that this metopic suture is persistent in some individuals even after fusion of the frontal bones after six years and it is called as Persistent Metopic Suture. It is sometime wrongly diagnosed as fracture of skull. But a suture is different from fracture. So this study will help to sort out the importance of studying persistent metopic suture in neurological examination

Key words: Metopic suture, Metopism, Frontal bone, Adult skull

INTRODUCTION

Metopic suture connects the two frontal bone in developmental stage. It is a kind of dentate suture and is seen in infants. It usually **closes at an age of 6 years** when the two frontal bones fuses together. Sometimes the metopic suture persists in adults even after fusion and it is called as **Persistent Metopic Suture**. The persistent metopic suture may occur as two forms

- Complete{METOPISM}- extending from bregma (anterior frontanelle) till the nasion and
- Incomplete(Partial) -extending from nasion not till bregma or from bregma not till nasion.

The incomplete metopic suture occur in different forms **U shape, V shape and Linear**. If the metopic suture does not persist or if fused at an early stage it causes Trigonocephaly. This leads to increased intracranial pressure during development due to lack of space for the intracranial structures which subsequently may leads to impairment of vision, mental development, sleeping and individual development.

MATERIALS AND METHODS

The study was undertaken in the department of anatomy Saveetha Dental College.

Sample size:

50 dry south Indian adult skulls were examined.

Samples

The samples studied were adult South Indian dry skulls It was obtained from the collection of Saveetha Dental College

Method:

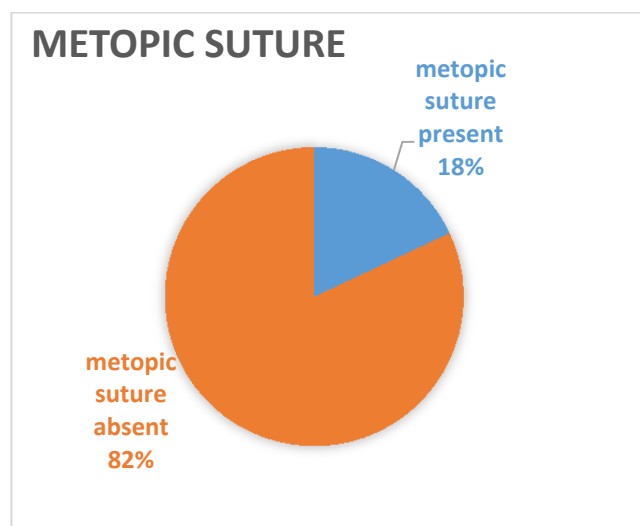
Direct examination of the dry skulls through naked eye Both complete and partial Metopic suture were observed and their shapes were also recorded.

RESULTS:

Out of 50 skulls studied there were 9(18%) skulls with Metopic Suture.(Pie chart 1)

7 had partial Metopic Suture[Image1,2,3] and 2 had Metopism [Image 3,5]

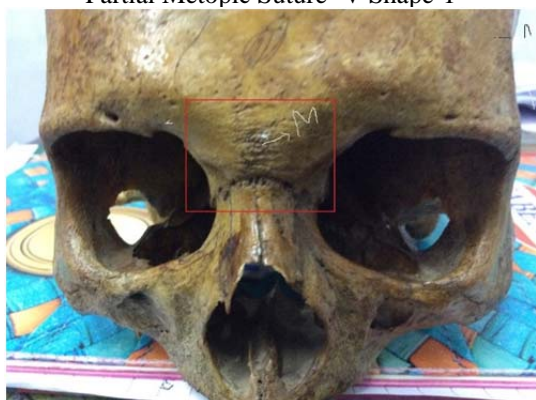
PIE CHART 1



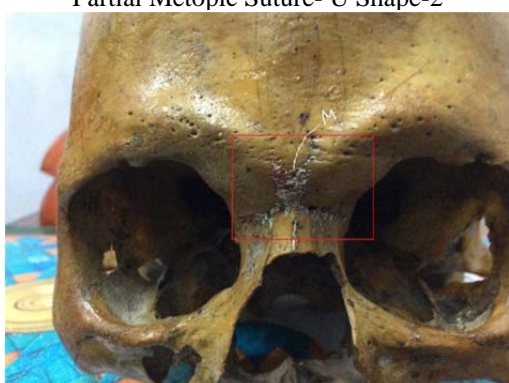
From the former research many of the researchers across the world came to different conclusion. For example the study of Shanta Chandrasekaran, Deepti Shastri who has studied 160 skulls in V.M.K.V.Medical College vinayaka Mission University, Salem has found 5% of metopism and 40% of incomplete metopic suture. So the occurrence of the complete and incomplete metopic suture is different in different areas of the world.

IMAGES

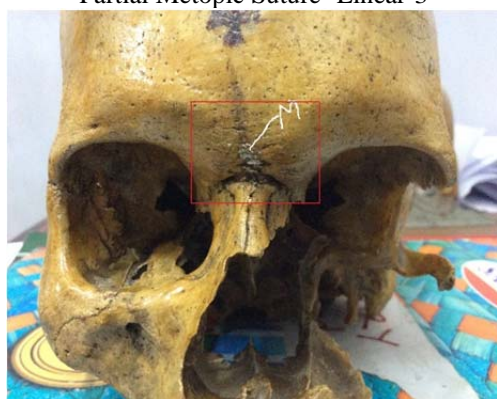
Partial Metopic Suture- V Shape-1




Partial Metopic Suture- U Shape-2



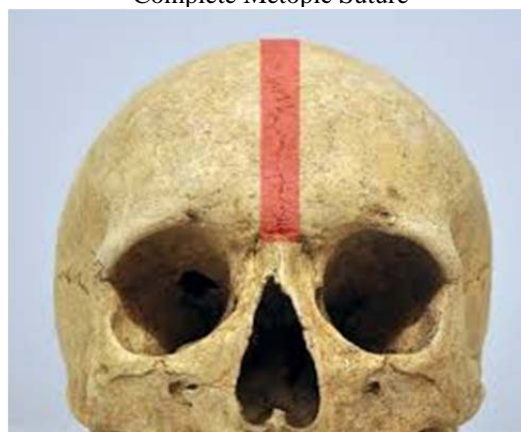
Partial Metopic Suture- Linear-3



Complete Metopic Suture-4



Complete Metopic Suture



DISCUSSION

The incomplete metopic suture has various shapes. It include U shape, V shape or occur as linear In present study we observed 2 skulls with U shape and one with linear. The observation and knowledge of metopic suture is Important as it is important for radiologist and neurologist, as it is mistaken as fracture. The basic difference between Fracture and suture will help us to differentiate it. The differential diagnosis include suture has well defined edges while Fracture has irregular edges. Moreover suture has interlocking edges. Suture is present in midline but fracture is not. Present study is closely related to the study Incidence of the metopic suture in adult by .M L Ajmani et.al in which they studied adult nigerian skulls. Also in the present study is also related to METOPIC SUTURE – INCIDENCE AND MORPHOLOGY IN SOUTH INDIAN HUMAN ADULT SKULLS CS Santhosh et.al. In the study of 1 Shanta Chandrasekaran, Deepti Shastri the studied out of 160 skulls 72 had metopic suture in which 5% had metopism and 40% had incomplete metopic suture. 2 In the study of .Hussain Saheb S*, Mavishetter G F, Thomas S T, Prasanna L C observed 3.2% metopism and 26% of incomplete metopic suture. 3 In the study of William F Masih, Sumit Gupta, PK Saraswa got 6.5% of metopism and 34% of incomplete metopic suture. 4 IN the study of Anjoo Yadav, Vinod kumar RK Srivastava observed 3.4% of metopism and 14.6% with incomplete metopic suture. In the study made by Agarwal, S. K., Malhotra, V. K. & Tewari, S. P. 5 in this study 3.4% metopism seen and 34.9% incomplete metopic suture.

CURRENT STUDY

	Total number of skulls studied	Metopism	Partial or incomplete metopic suture	Total number of skulls having metopic suture
Number of skulls	50	2	7	9

Sl.no	Workers	Year	No. of skulls studied	Metopism	Metopic suture
1	Marco Antonio Sant'Ana Castilho Juliano Yasuo Oda Débora de Mello Gonçales Sant'Ana		71, the Laboratory of Human Anatomy of the Paranaense University UNIPAR	7.4%	32.39%
2	Shanta Chandrasekaran, Deepti Shastri	2011	160,V.M.K.V.Medical College, Vinayaka Mission University, Salem	5%	40%
3	Hussain Saheb S Mavishetter G F, Thomas S T, Prasanna LC	2010	125 ,Department of Anatomy , JJM Medical College, Davangere, Karnataka, India	3.2%	26.4%
4	Present study	2014	50 ,Saveetha dental college dept. of anatomy	4%	14%

CONCLUSION

Thus it was concluded that in the present study, it has been observed that 9 skulls with metopic suture. In that 7 is incomplete and 3 is complete. This will be important for neurologist doing surgery as mostly it is mistaken as fracture or crack

REFERENCE

1. The study of metopic suture in south indian skulls shanta chandrasekaran, deepti shastri
2. incidence of metopic suture in adult south indian skulls.hussain saheb s*, mavishetter g f, thomas s t, prasanna l c department of anatomy 2010
3. Autopsy of metopic suture in human skulls in western rajasthan by william f masih, sumit gupta, pk saraswat
4. Study of metopic suture by anjoo yadav, vinod kumar, rk srivastava
5. Incidence of metopic suture by m l ajmani, r k mittal, and s p jain
6. Berry, a. C. (1975). Factors affecting the incidence of non-metrical skeletal variations. *Journal of anatomy* 120, 519-535.
7. Study of metopic suture in human skulls by bilodi ak , agarwal bk , mane, kumar
8. Das a.c., saxena, r. C. & beg, m. A. Q. (1973). Incidence of metopic suture in u.p. Subjects. *Journal of the anatomical society of india* 22, 140.