

A Study of Morphological Variation of Lingula and Coronoid Process of Adult Human Dry Mandibles

Kayalvili Sanmugam

Saveetha Dental college and Hospitals
Chennai-77

Abstract:

The study aims to analyse the variation in the shapes of lingula and coronoid process of adult human dry mandibles. The objective of the study is to classify the different forms of presentation of lingula and coronoid process in hundred dry adult human mandibles (200 sides) in Anatomy Lab, Saveetha Dental College. Three variants of coronoid process were evident with triangular being the highest 49%, hook 27% and rounded 24%. Whereas, four variants of lingula process were evident with triangular being the highest 48%, truncated 26%, assimilated 19% and nodular 7%. Knowledge of various morphological shapes of the coronoid and lingula process of mandible is useful to dental surgeons in oral and maxillofacial surgical procedure. This helps them to preserve the important structures during surgical interference of mandible. It is also useful in anthropological studies and in forensic dentistry.

Keywords: Mandible, coronoid process, lingula process

INTRODUCTION:

The mandible is the strongest, lowest and largest bone in the face. It has a horizontally curved body that is convex forwards and two broad rami that ascend posteriorly. The rami bear the coronoid and condylar processes. The coronoid process projects slightly forward and upward as a triangular plate of bone.^[1] Temporalis muscle is attached to the medial surface of the coronoid process.^[2] The variation in the shape of coronoid process are like triangular, rounded and hook shaped. The morphological variation in the shape of coronoid process may be due to the hereditary or functional changes and has a correlation with the mode and attachment of temporalis muscle. The shape of coronoid process acts as an evolutionary marker and is useful in anthropological studies and in forensic studies. The coronoid process is of clinical significance to the maxillofacial surgeons for reconstructive purposes.^[3] A local bone graft from Coronoid process of mandible can also be used.^[4] Coronoid process also has been used as a donor site for sinus augmentation.^[5]

The lingula of mandible is a tongue shaped bony projection on the medial aspect of ramus of mandible. It acts as an important landmark as it lies in close proximity to the mandibular foramen. The lingual is used for identifying the site for injection of local anaesthetics or for excision of nerve for facial neuralgia.^[6] Since the inferior alveolar nerve enters the mandibular foramen to supply the structures of the lower jaw, the relationship of lingula to the inferior alveolar nerve is clinical significance to dental surgeons.^[7] There are many variations in the shape of lingula like triangular, truncated, nodular and assimilated.

MATERIALS AND METHOD:

The present study was undertaken in hundred dry adult human mandibles on either sides to determine the variations in the shape of coronoid and lingula process of mandible from Anatomy Lab, Saveetha Dental College. The different shapes of coronoid and lingula process were compared for difference on either side. The variations of the coronoid and lingula process of mandible were observed and their photographs were taken for documentation.

OBSERVATION AND RESULTS:

According to the shape of the coronoid process, they were classified into 3 types:

- 1) Triangular → tip pointing directly upwards
- 2) Rounded → tip rounded
- 3) Hook → tip pointing backwards

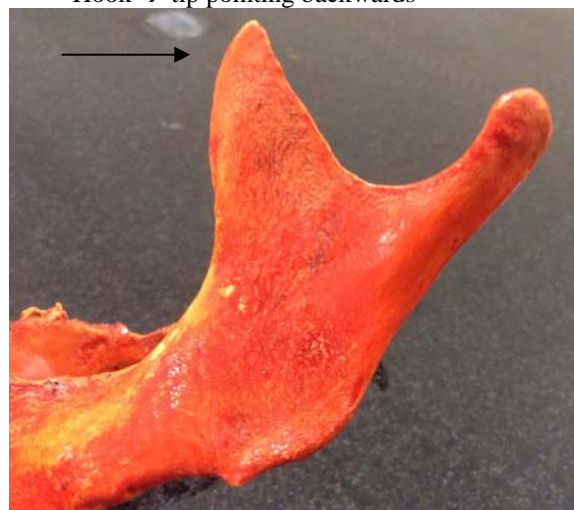

Figure 1: Triangular coronoid process

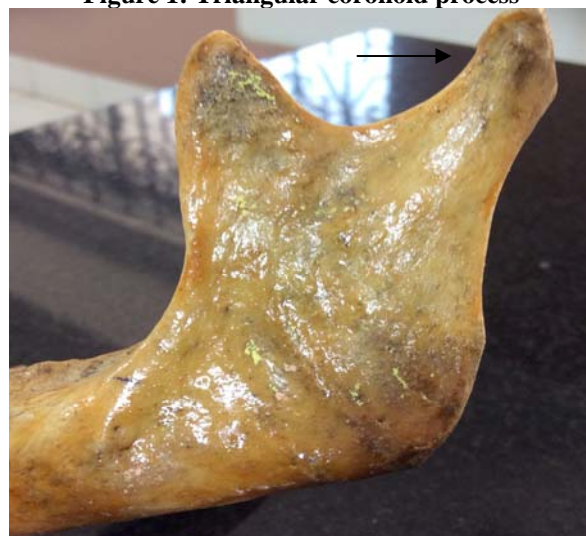

Figure 2: Rounded coronoid process

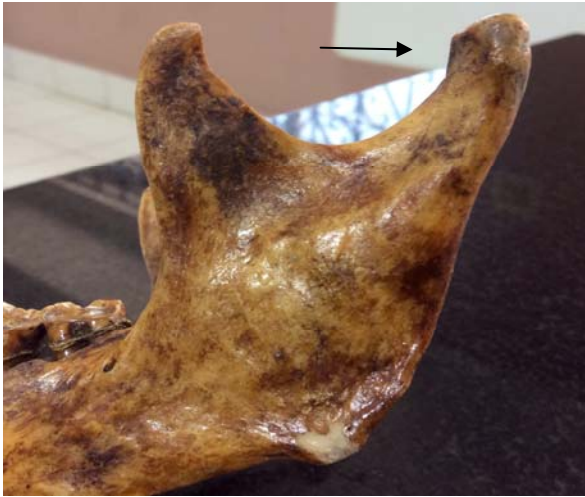

Figure 3: Hook shaped coronoid process

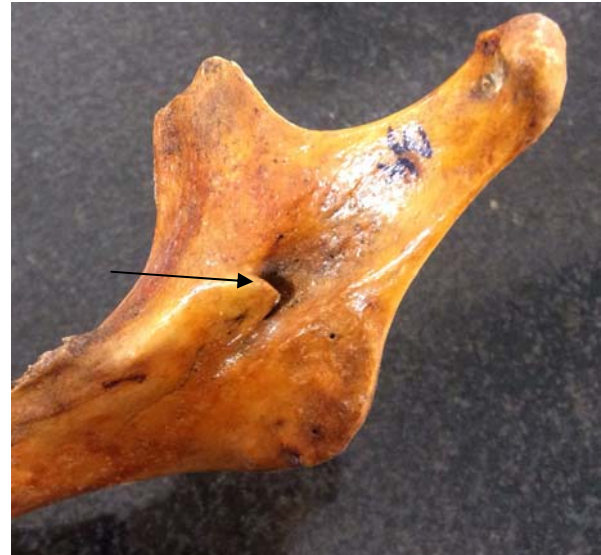

Figure 5: Triangular lingula process

Table 1: Distribution of various shapes of coronoid process

Types	Shapes of coronoid process	%	Bilateral	Unilateral	
				Right	Left
1	Triangular	98(49%)	76	9	13
2	Rounded	48(24%)	26	15	7
3	Hook	54(27%)	32	6	16

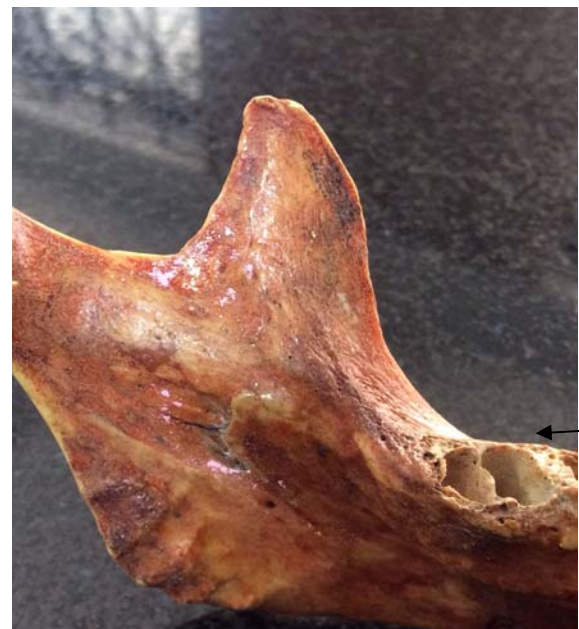

Figure 6: Truncated lingula process

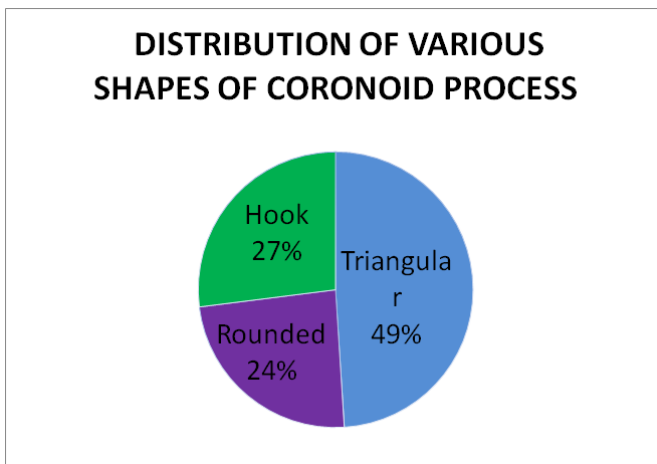


Figure 4: Percentage of various shapes of coronoid process

Out of total 200 sides (100 mandible), incidence of triangular coronoid process was found in 98 sides (49%). In 38 mandible (76 sides) was found bilaterally and in 22 mandibles it was present unilaterally. Coronoid process with rounded tip was found in 48 sides (24%). In 13 mandibles (26 sides) it was present bilaterally and in 22 mandibles it was unilaterally. Incidence of rounded coronoid process was the least. Incidence of hook shape coronoid process was found in 54 sides (27%). In 16 mandibles (32 sides) it was present bilaterally and in 22 mandibles it was present unilaterally.

According to the shape of lingula process, they were classified into 4 types:

- 1) Triangular
- 2) Truncated
- 3) Assimilated
- 4) Nodular



Figure 7: Assimilated lingula process

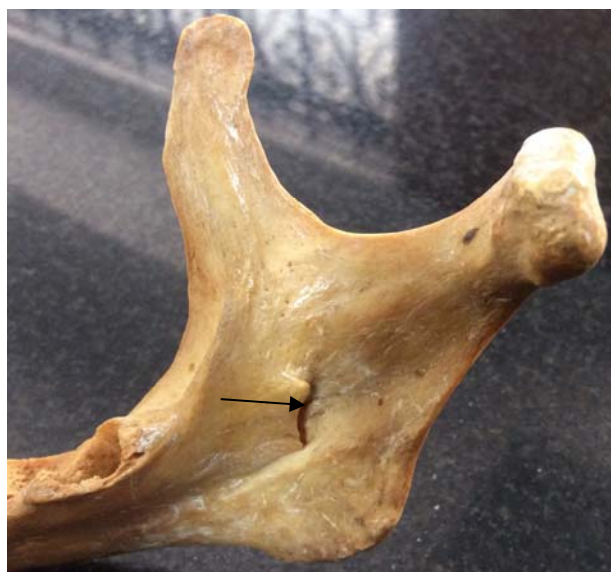

Figure 8: Nodular lingula process

Table 2: Distribution of various shapes of lingula process

Types	Shapes of lingula process	%	Bilateral	Unilateral	
				Right	Left
1	Triangular	96 (48%)	90	1	5
2	Truncated	52 (26%)	46	4	2
3	Assimilated	38 (19%)	32	5	1
4	Nodular	14 (7%)	10	2	2

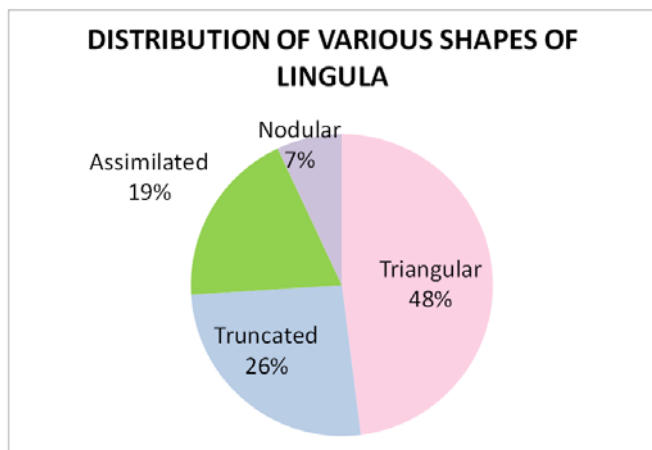


Figure 9: Percentage of various shapes of lingula process

Out of total 200 sides (100 mandible) studied, incidence of triangular lingula process was found in 96 sides (48%). In 45 mandible (90 sides) was found bilaterally and in 6 mandibles it was found unilaterally. Truncated lingula process was found in 52 sides (26%). In 23 mandibles (46 sides) it was found bilaterally and in 6 mandible it was found unilaterally. Assimilated lingula process was found in 38 sides (19%). In 16 mandibles (32 sides) it was found bilaterally and in 6 mandibles it was found unilaterally. Nodular lingula process was found in 14 sides (7%). In 5 mandibles (10 sides) it was found bilaterally and in 4 mandibles it was found unilaterally.

DISCUSSION:

Coronoid process which means ‘crow’ is the anterior bony projected part of ramus of mandible. Anatomical variations in the shape of coronoid process can result in narrowing of the vestibular space due to the close proximity of the medial aspect of the coronoid process to the distal molar teeth and may cause impingement, which results in restriction of mouth opening and mandibular hypomobility. Ccoronoid process is described as a flat triangular process.^[1] The present study showed triangular shaped of coronoid process were most prevalent followed by hook shaped and rounded which was in accordance with findings of Isaac et al (2001)^[9], Tanveer A et al (2011)^[10] and Nirmale et al (2012)^[11] The difeference in the shape of coronoid process had been associated to various factors like attachment and action of temporalis action, unilateral chewing habit and hormonal factors. The coronoid process makes an excellent donor graft site for reconstruction of orbital floor deformities. Clauser et al 1995 reported the use of temporalis myofascial flap both as a single and as composite flap with cranial bone. Coronoid process or skin island can be used in all aspects of reconstructive craniomaxillofacial surgery including trauma, deformities, tumors, temporomandibular joint ankylosis and facial paralysis.

Whereas, lingula meaning ‘little tongue’ has been described in relation to the mandibular foramen as a bony elevation partially covering it. Lingula was described by Johannes-Baptist Spix in 1815 and was therefore named ‘Spix’s ossicle or spine’ (Dobson 1962). The present study showed triangular shaped of ligula process were most prevalent followed by truncated, assimilated and nodular. Nicholson (1985)^[12] and DuBrul (1988)^[13] reported the presence of various shapes but did not provide details about the various types and incidence. The sphenomandibular ligament is considered an accessory ligament of the temporomndibular joint because its lower attachment to the lingula is at the axis of rotation when the mouth is opened. In a study to localise the mandibular the mandibular foramen, Nicholson (1985) examined adult mandibles of East Indian ethnic origin and used the lingula as the reference point to standardise the measurements. The height and the shape of the lingula revealed great variation, but no description of these was presented.

CONCLUSION:

In the present study various shapes of coronoid and lingula process is evaluated. The triangular shape was the highest in both the coronoid (49%) and lingula process (48%) of mandible. Knowledge of various morphological shapes of the coronoid and lingula process of mandible is useful to dental surgeons in oral and maxillofacial surgical procedure. This helps them to preserve the important structures during surgical interference of mandible. It is also useful in anthropological studies and in forensic dentistry.

REFERENCES:

- 1) Standring S, Collins P, Healy JC, Wigley C, Beale TJ. Mandible: Infratemporal and pterygopalatine fossae and temporomandibular joint. Grey's Anatomy-The Anatomical Basis of Clinical Practice, Fortieth edition. Churchill Livingstone, Elsevier. 2008: 530-532
- 2) Prajapati VP, Ojaswini Malukar O, Nagar SK. Variations in the Morphologica Appearance of the Coronoid Process of Human Mandible. Nat J Med Res. 2011;1:64-66
- 3) Shakya S.Ongole R, Nagraj SK. Morphological of Coronoid Process and Sigmoid Notch in Orthopantomograms in South Indian Population. World J Dent. 2013; 4:1-3
- 4) Dr Smita Tapas. Morphological Variations of Coronoid Process in Dry Adult Human Mandibles. Indian Journal of Basic and Applied Medical Research; March 2014; Vol-3, Issue-2,:401-405
- 5) Kim YK, Hwang JW, Lee HJ, Yun PY. Use of Coronoid Process as a Donor Site for Sinus Augmentation; A Case Report. The Int J Oral Maxillofacial Implants. 2009; 24:1149-1152
- 6) Tuli, A., R. Choudhry, S. Choudhry, S. Raheja, and S. Agarwal. "Variation in Shape of the Lingula in the Adult Human Mandible." J Anatomy Journal of Anatomy 197.2 (2000): 313-17. Web.
- 7) V.K. Nirmale, U. W. Mane, S.B. Sukre, C.V. Diwan. Morphological Features of Human Mandible. International Journal of Recent Trends in Science and Technology, ISSN 2277-2812 E-ISSN 2249-8109, Volume 3, Issue 2, 2012: 38-43
- 8) Isaac B, Holla SJ. Variations in the Shape of the Coronoid Process in the Adult Human Mandible. J Anat. Soc. India. 2001; 50(2) : 137-139
- 9) Khan TA., Sharieff JH. Observation on Morphological Features of Human Mandibles in 200 South Indian Subjects. Anatomica Karnataka. 2011: 5(1): 44-49
- 10) Nirmale VK, Mane UW, Sukre SB, Diwan CV. Morphological Features of Human Mandible. Int J of Recent Trends in Sci Technol. 2012; 3 (2): 38-43
- 11) NICHOLSON M L A study of the position of the mandibular foramen in the adult human mandible. Anatomical Record, 212,110±112, 1985.
- 12) DuBRUL E L, Sicher and DuBrul's Oral Anatomy, 8th edn, pp. 32±35. Tokyo and New York: Ishiyaku Euro America, 1988.