

# Stages of Third Molar Development Examination

**Giftson Rajarajan, D, Dr.Saravana Pandian,**  
*Saveetha Dental College, Vellepanchavadi, Chennai*

## INTRODUCTION:

Third molar evaluation plays an important role in the fields of orthodontics, pedodontics, oral surgery and in forensic odontology.(1) Moreover estimation of age is an important criteria in establishing the identity of individuals. Since dental structures are durable and survive disasters and can survive fires or bomb blasts and mass disasters, they can be used to estimate the age of the deceased individual. Difficulty in age estimation after 14 years of age has shifted the focus on to the third molars also referred to as the 'wisdom teeth.' The multiple teeth in various stages if tooth development provide sufficient data for age determination.(2) But this is only individuals who are less than 14 years of age.(8)

The assessment of third molar development from initiation to its complete development in terms of various developmental stages can be implemented in age estimation of human being, especially after 14 years. Radiographic evaluation of the presence, position and degree of third molar formation can be made use in human age estimation.(3) The current study aimed to evaluate the development of third molar in relation to chronological age.

## MATERIALS AND METHODS:


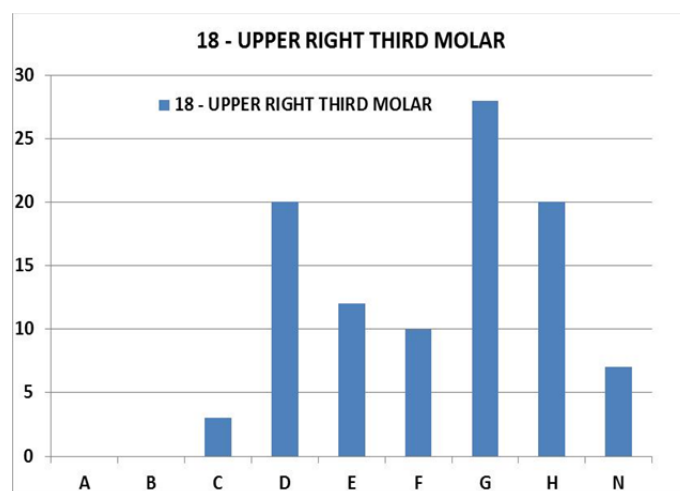
This study consisted of a sample size of 100 subjects in the age group of 14 to 20 years. For each subject an orthopantomogram was taken on an OPG machine. The selection criteria for inclusion in the sample included subjects who had not undergone any prior medical or surgical treatment that could affect the presence and development of the third molars in addition to no pathologies in the subject.

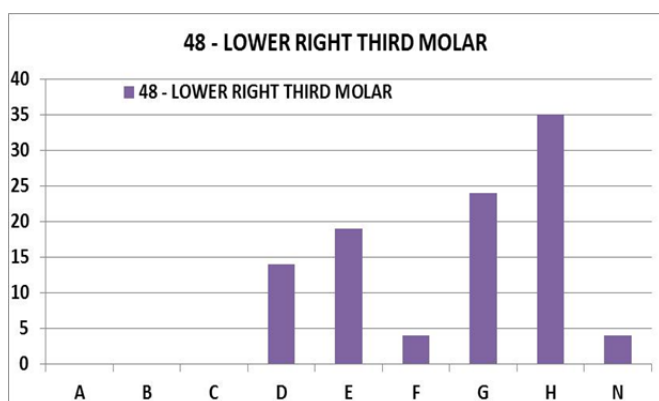
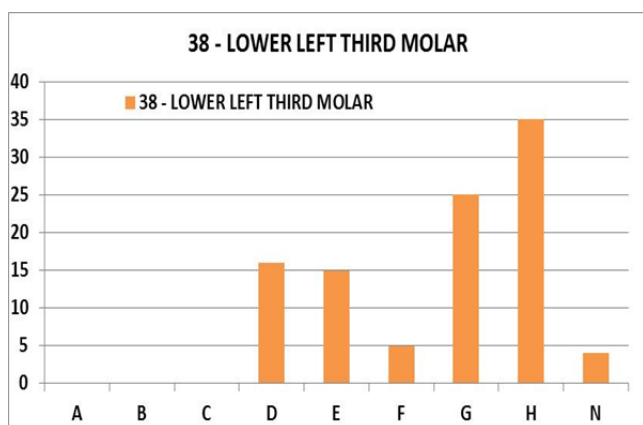
To assess the developmental stages of third molars of maxilla and mandible, the staging system described by Demirjian was adopted.(4) Eight developmental stages were considered for each third molar tooth; from the appearance of the uncalcified tooth germ to the complete apical closure, and the stage N,(5) which designates the total absence of tooth formation (absence or no evidence of bone crypt). Each particular stage corresponds to a particular developmental score, ranging from A to H.(6) For each case, the developmental stage was determined for all third molars present on the orthopantomogram.(7)

- A- Mineralised cusp tips, not yet coalesced
- B- Mineralised cusp United
- C- The crown is approximately half formed
- D- Crown formation is complete to the dentino enamel junction
- E- Root formation has begun
- F- Root length at least as great as crown length
- G- Parallel root wall with open apices
- H- Apices are completely closed
- N- No tooth formation

Table:

	18	28	38	48
<b>A</b>	0	0	0	0
<b>B</b>	0	0	0	0
<b>C</b>	3	3	0	0
<b>D</b>	20	14	16	14
<b>E</b>	12	15	15	19
<b>F</b>	10	9	5	4
<b>G</b>	28	31	25	24
<b>H</b>	20	19	35	35
<b>N</b>	7	9	4	4





**DISCUSSION:**

The present study included individuals within the age group of 14 to 20 years (7)so that the development of third molars can be studied right from its initiation to root completion.

The study shows that there are no teeth in the first two developmental stages in individuals of this age group. 18 was in the G stage of development in 28 individuals.

28 was in the G stage of development in 31 individuals. This shows that majority of the individuals had there maxillary third molars in the G stage of development. However both 38 and 48 had 35 teeth in the H stage of tooth development. Based on this we can conclude that the mandibular third molars develop faster than their maxillary counter parts.

There are 7 individuals who are missing a 18 and 9 individuals who are missing a 28. Whereas the number of individuals where the mandibular third molars have not yet developed is slightly lower- only 4 individuals have a missing 38 and 48.

**CONCLUSIONS:**

In forensic odontology, if the age of the person can be accurately estimated it will significantly narrow the field of possible identities needed to establish a positive identification.(9) The use of third molar teeth in age estimation has forever been questioned in the literature.(10) Although the reliability of third molars in age estimation has been evaluated by several research groups, consensus on the usefulness of these teeth has not yet been reached.(11) Third molar has always been categorised as a nonideal developmental marker owing to its variability, still it can be used as an aid in age estimation due to inaccuracy of skeletal predictors of age in adults.

**REFERENCE:**

- [1] Rai B. Age Determination on Impacted Teeth: A New Concept. *Adv in Med Dent Sciences*.2007;1(1):5-7.
- [2] Star H, Thevissen P, Jacobs R, Fieuws S, Solheim T, Willems G. Human Dental Age Estimation by Calculation of Pulp-Tooth Volume Ratios Yielded on Clinically Acquired Cone Beam Computed Tomography Images of Monoradicular Teeth. *J Forensic Sci*. 2011;56:S77-S82
- [3] Aggrawal. A. "Estimation of age in the living: in matters civil and criminal") *J Anat*. 2009doi:10.1111/j.1469-7580.2009.01048.x. PMID 19470083
- [4] Demirjian A, Goldstein H, Tanner JM. A new system of dental ageassessment. *Human biology*.1973;45(2):211-27. [\[PubMed\]](#)
- [5] Kanmani R, Srinivasan SV, Jonathan Daniel M. Mandibular Third Molar Development As An Indicator Of Chronological Age For A Pondicherry Population of Southern. *India J Dent*. 2012;2:153-8.
- [6] Darji J, Govekar G, Kalele S, Hariyani H. Age Estimation from Third Molar Development A Radiological Study. *J Indian Acad Forensic Med*. 2011;33:130-4.
- [7] Panchbhai A. Dental radiographic indicators, a key to age estimation. *Dentomaxillofac Radiol*.2011;40:199-212.
- [8] Hegde RJ, Sood PB. Dental Maturity as an indicator of chronological age: Radiographic evaluation of Dental age in 6 to 13 years children of Belgaum using Demirjian Methods. *J Indian Socof Pedo Prev Dent*.2002;20:132-8
- [9] Mincer HH, Harris EF, Berryman HE. The A.B.F.O. study of third molar development and its use as an estimator of chronological age. *J Forensic Sci*. 1993;38(2):379-90.
- [10] Kullman L, Johanson G, Akesson L. Root development of the lower third molar and its relation to chronological age. *Swed Dent J*. 1992;16:161-7
- [11] Kumar VJ, Gopal KS. Reliability of age estimation using Demirjian's 8 teeth method and India specific formula. *Forensic Dent Sci*. 2011;3(1):19-22.