

Awareness of Quid Associated Oral Lesions among Dental Students

Dr. M.P. Santhosh Kumar M.D.S.,

Reader,

Department of Oral and Maxillofacial Surgery

Saveetha Dental College And Hospital

162, Poonamallee High Road, Velappanchavadi, Chennai

Tamilnadu 600077,India

Harshini A.K.

Final Year Student

Saveetha Dental College

Abstract

Objective:

To assess the knowledge and awareness of quid associated oral lesions among under graduate dental students.

Methods:

A validated questionnaire of 10 questions, pertaining to quid associated oral lesions was distributed randomly among 50 students belonging to Final year, and internship (fifth year trainee) of undergraduate dental program in Saveetha Dental College and Hospital, Saveetha university, Chennai. The data extracted were tabulated, statistically analyzed and results obtained.

Results:

80% of students were aware of the components of quid. 92% of them were sure that quid chewing causes oral cancer over a period of time. 92% of students said quid chewing produces lichenoid reaction on the oral mucosa. 86% of students answered that quid chewing causes localised lesions confined to the area it is placed.

Conclusion:

This study shows that most of the undergraduate dental students are well aware of quid and the various oral lesions induced by the usage of quid. Morbidity and mortality are likely to be reduced if future dentists know how to detect early mucosal changes associated with quid usage. It is the duty of dentists to give proper oral health education and insist the patients on cessation of tobacco consumption in any form.

Keywords-Quid, Arecanut, Oral submucous fibrosis, Premalignant lesions, Mucosal changes, Betel quid, Betel leaf

INTRODUCTION

Quid is a mixture of substances which is placed in the mouth, where it is sucked or is actively chewed over an extended period of time. It usually contains either tobacco or areca-nut or both, in raw or in any manufactured or processed form which are considered to be the basic ingredients.[1] Betel quid is also known as paan, which varies in its composition, from community to community and between individuals, although the major constituents are areca-nut and slaked lime (from limestone or coral), tobacco and is wrapped within a betel leaf . The paan is placed between the teeth and the Buccal mucosa, and is either chewed or sucked for several hours.[2] It produces a feeling of euphoria and well-being.[3] The mechanism behind this is the release of an alkaloid from the areca-nut. Some other substances may also be added such as grated coconut or spices like aniseed, peppermint, cardamom and cloves, based on the local preference.[4]Tobacco which is a basic ingredient, is associated with an increased risk of oral

cancer. The lime releases reactive oxygen species from extracts of areca-nut which might be the contributing factor for cytogenic damage involved in oral cancer.[5] A synergistic increase in risk of oral cancer has been demonstrated among those people who consume alcohol, smoke and chew quid.[6,7] Paan has variants which use areca-nut alone along with certain sweeteners, to make it attractive to younger children. It is sold under various names such as sweet supari, gua , mistee , mawa. Some other variants are kiwam , zarda , mitha pan which includes tobacco and a variety of other substances.[8]

The first initiative to bring about a consensus on the oral mucosal changes, to betel quid use and tobacco chewing was done in 1996 in Malaysia where a workshop was held in this regard. In this workshop, basic terminologies like, definition of quid, criteria for recording quid or tobacco chewing habits were made.[1]

3 basic categories of quid are:

- Quid with areca nut but without any tobacco products, which may involve chewing only the areca nut or areca nut quid wrapped in betel leaf (paan).
- Quid with tobacco products but without areca nut, including chewing tobacco, chewing tobacco plus lime, mishri (burned tobacco applied to the teeth and gums), moist snuff, dry snuff, niswar (a different kind of tobacco snuff) and naas (a stronger form of niswar).
- Quid with both areca nut and tobacco products (paan with tobacco).

Oral mucosal lesions and conditions associated with the use of areca-nut as well as tobacco have been stated.

The International Agency for Research on Cancer concluded that the habit of chewing quid that contains tobacco is carcinogenic to humans.[4]

Two types of quid related lesions have been recognized:

- 1) Lesions or conditions which are diffuse, involving more than one site or represent a wide spread alteration, due to mechanical or chemical trauma. Examples are chewer's mucosa.
- 2) Lesions that are localized to the site where the quid is regularly placed.[9]

The following are some of the lesions and conditions caused by the usage of Quid:

Betel Chewer's Mucosa:

This is a condition in which there is a tendency for the oral mucosa to desquamate or peel because of the direct action of quid or due to trauma as a result of constant chewing.[10]

Quid Induced Lesion:

It is a localized lesion of the oral mucosa at the site of regular placement of quid.

Areca Nut Related Lesion:

Areca nut chewers may have clinically healthy mucosa with no textural or colour changes, but the buccal mucosa may show an ill-defined whitish grey discoloration which cannot be rubbed.

Oral Submucous Fibrosis:

It is an insidious, precancerous, chronic disease that affects the entire oral cavity and at times the pharynx too. The

main problem with this condition is difficulty in mouth opening.[11]

Betel Quid Lichenoid Lesion:

It resembles lichen planus. It is exclusively found among betel quid users.[12]

Dentists play an important role in the prevention of oral cancer because they are the first to detect oral cancerous lesions at its earliest stages. Many dentists are unaware of the prevalence of the quid or paan habit in the population. The recognition of the role of such products in the development of oral precancer and cancer is of great importance to the dental practitioner. A variety of oral mucosal lesions and conditions have been reported in association with quid and tobacco use, and the association of these conditions with the development of oral cancer emphasizes the importance of education to limit the use of quid. Very few studies are done to assess the knowledge of quid associated lesions among dental students. The aim of this study is to analyse the awareness of quid induced oral lesions, among dental undergraduate students of our institution.

MATERIALS AND METHODS

Year of Study

The study was conducted during the academic year in February 2016.

Study Population and Location

This study was conducted among the dental students who were attending the Final year, and internship (fifth year trainee) of graduate program in Saveetha Dental College and Hospital, Saveetha university, Chennai.

Study Sample Size

50 students were enrolled randomly in the study from final year, and intern students who were present at the day of study.

Questionnaire

A validated questionnaire of 10 questions was distributed among all the students of the study and the questions were designed to assess their basic knowledge and awareness about quid associated oral lesions.[figure 1]. The data extracted were tabulated, statistically analyzed and results obtained.

Awareness of quid associated oral lesions among U.G students of Saveetha dental college :

1. The term quid denotes mixture of substances with either tobacco, areca nut or both as Asif ingredients
A) Yes
B) No
 2. Quid chewing causes diffused wide spread lesions involving the oral mucousa
A) Yes
B) No
 3. Quid chewing induces chewer's mucosa to peel off and desquamation of oral mucosa
A) Yes
B) No
 4. Quid chewing causes localised lesions confined to the region it is placed
A) Yes
B) No
 5. Quid associated lesions can produce colour change of the mucosa
A) Yes
B) No
 6. Quid chewing causes oral cancer over a period of time
A) Yes
B) No
 7. Quid chewing causes lichenoid reaction on the mucosa
A) Yes
B) No
 8. Restraining from the habit reverts the mucosal change that is established
A) Yes
B) No
 9. Use of quid causes stretching of the oral mucosa
A) Yes
B) No
 10. Do you think dentist can act as the first line in diagnosis of premalignant lesions and other maxillofacial cancers?
A) Yes
B) No
-

Figure . 1 Questionnaire:

RESULTS

80% of students were aware of the components of quid, 84% of students thought quid chewing causes diffuse wide spread lesions and 88% of participants were aware that quid chewing can cause desquamation of oral mucosa. 86% of students answered that quid chewing causes localised lesions confined to the area it is placed , 94% of participants said quid causes colour change on the oral mucosa and 92% of them were sure that quid chewing

causes oral cancer over a period of time. 92% of students said quid chewing produces lichenoid reaction on the oral mucosa, 46% of students answered the lesion produced by quid chewing can be reverted back on cessation of the habit while 54% disagreed and 96% of them replied that use of quid causes stretching of oral mucosa. Majority [96%] of students agreed that dentists are the first personnel in indentifying premalignant and malignant lesions of the oral cavity. [Figure 2].

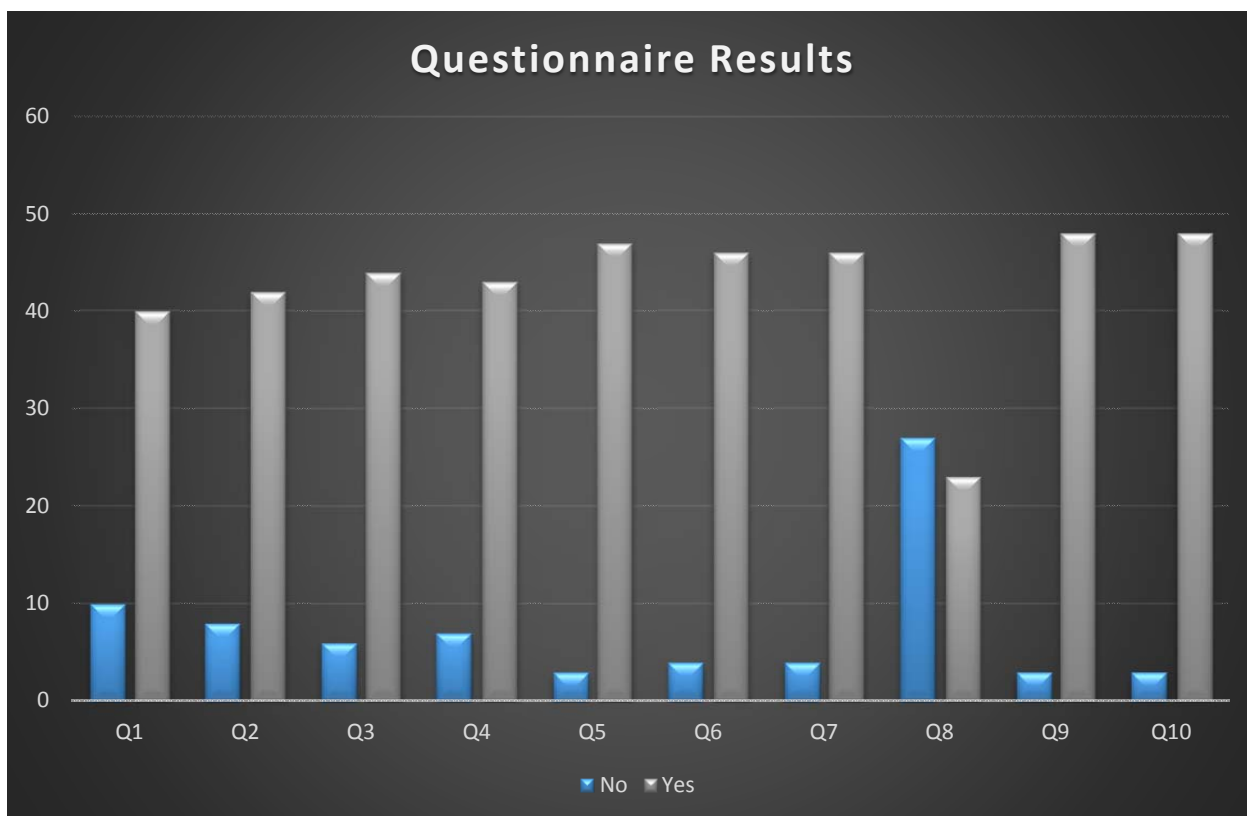


Figure 2. Awareness Of Quid Associated Oral Lesions Among Undergraduate Dental Students

DISCUSSION

Quid is a mixture of substances that are chewed or sucked in the mouth. The main ingredients are tobacco and /or areca nut, with some flavouring agents like grated coconut etc. The lesions caused by chewing quid have been classified into 2 types: localized and diffused lesions. Example of diffused lesion is chewer's mucosa and localized lesion include quid – induced lesion. Quid usage can also cause thickening of mucosa, fibrous bands in the mucosa as in the case of oral submucous fibrosis, colour change, wrinkling of mucosa as seen in quid induced lesion, and ulcerations are observed to be greater among quid chewers than smokers.

There seems to be an association between the use of quid that incorporates tobacco and the occurrence of white lesions [oral cancer].[13] This highlights the importance of education on limiting the use of quid. The intraoral locations of white lesions are generally influenced by the person's specific tobacco habits, and there seems to be a significant relationship between tobacco cessation and a decrease in the incidence rate of white lesions. The pattern and the intensity of the lesions, depends on the individual's chewing habit and contents of the quid.[14] No specific test is available to confirm whether a particular oral lesion was caused by the patient's quid habit. The diagnosis must be made on the basis of a history of repeated exposure to betel quid containing certain ingredients, the clinical appearance and the texture of the tissue (especially for oral submucous fibrosis [OSMF]). Incisional biopsy is recommended, specifically biopsy of the most severely affected area (or

any area of ulceration) to rule out squamous cell carcinoma.[15] Histopathologic examination may show a dense, chronic inflammatory infiltrate with epithelial changes ranging from atrophy accompanied by hyperkeratosis to dysplasia to frank malignancy. The management of such oral lesions depends on the type of quid-related lesion. The first option is no treatment, accompanied by discontinuation of the betel quid habit and appropriate follow-up. Mild cases of OSMF or patients with limited jaw opening that still permits reasonable eating abilities and access for oral hygiene and dental care may be treated without intervention but with a focus on quitting the quid habit. Severe cases can be successfully treated, with return to near-normal jaw opening, by complete excision and surgery using mucosal or nonvascularized split-thickness skin grafts of the affected areas.[15] Successful prevention in the early stages of these conditions may lead to improvement in symptoms. However, when the patient continues his or her betel quid habit, the prognosis for an untreated lesion, regardless of its colour, degree of thickening, ulceration of the epithelial surface or presence of thick fibrous bands, is progressive worsening, with a high risk for squamous cell carcinoma. An active preventive approach is required to limit the potential for the development of oral cancer.[16]

Our study was done to evaluate the level of awareness about quid and the various oral lesions associated with quid usage among dental students of our college. It revealed majority of students were aware of the components of quid and the localised and diffuse lesions that can arise in oral cavity due to the usage of quid.

CONCLUSION

Quid chewing habit has got a lot of social and cultural implications in India. Due to its widespread nature dental practitioners should be well aware of premalignant and malignant lesions and or conditions caused by tobacco in any form, smoking or smokeless [quid][16]. This would help them in patient education, diagnosing lesions early and preventing malignant changes. This study shows that most of the undergraduate dental students are well aware of quid and the various oral lesions induced by the usage of quid. Morbidity and mortality are likely to be reduced if future dentists know how to detect early mucosal changes associated with quid usage. Educational programmes in the dental curriculum must adequately train students to detect early mucosal changes associated with use of betel quid and must emphasize them to take adequate personal and social history. It is the duty of dentists to give proper oral health education and insist the patients on cessation of tobacco consumption in any form.

REFERENCES

- Zain RB, Ikeda N, Gupta PC, Warnakulasuriya KAAS, van Wyk CW, Shrestha P, and other. Oral mucosal lesions associated with betel quid, areca nut and tobacco chewing habits: consensus from a workshop held in Kuala Lumpur, Malaysia, November 25–27, 1996. *J Oral Pathol Med* 1999; 28(1):1–4.
- Farrand P, Rowe RM, Johnston A, Murdoch H. Prevalence, age of onset and demographic relationships of different areca nut habits amongst children in Tower Hamlets, London. *Br Dent J* 2001; 190(3):150–4.
- Neville BW, Damm DD, Allen CM, Bouquot JE. *Oral and maxillofacial pathology*. 2nd ed. Philadelphia: W.B. Saunders Company; 2002. p. 349–50.
- International Agency for Research on Cancer. IARC monographs on the evaluation of the carcinogenic risk of chemicals to humans. Tobacco habits other than smoking; betel-quid and areca-nut chewing; and some related nitrosamines. Vol. 37. 291 pp. Lyon, France: IARC, 1985.
- Nair UJ, Obe J, Friesen M, Goldberg MT, Bartsch H. The role of lime in the generation of reactive oxygen species from betel quid ingredients. *Environ Health Perspect* 1992; 98:203–5.
- Gupta PC, Nandakumar A. Oral cancer scene in India. *Oral Dis* 1999; 5(1):1–2.
- Ko YC, Huang YL, Lee CH, Chen MJ, Lin LM, Tsai CC. Betel quid chewing, cigarette smoking and alcohol consumption related to oral cancer in Taiwan. *J Oral Pathol Med* 1995; 24(10):450–3.
- Shah B, Lewis MA, Bedi R. Oral submucous fibrosis in a 11-year-old Bangladeshi girl living in the United Kingdom. *Br Dent J* 2001; 191(3):130–2.
- Bhonsle RB, Murti PR, Daftary DK, Mehta FS. An oral lesion in tobacco-lime users in Maharashtra, India. *J Oral Pathol* 1979; 8(1):47–52.
- Reichart PA, Schmidtberg W, Scheifele CH. Betel chewer's mucosa in elderly Cambodian woman. *J Oral Pathol Med* 1996; 25(7): 367–70.
- Pindborg JJ, Bhonsle RB, Murti PR, Gupta PC, Daftary DK, Mehta FS. Incidence rate and early forms of oral submucous fibrosis. *Oral Surg Oral Med Oral Pathol* 1980; 50(1): 40–4.
- Daftary DK, Bhonsle RB, Murti PR, Pindborg JJ, Mehta FS. An oral lichen planus-like lesion in India betel-tobacco chewers. *Scand J Dent Res* 1980; 88(3):244–9.
- Gupta PC, Mehta FS, Daftary DK, Pindborg JJ, Bhonsle RB, Jalnawalla PN, and others. Incidence of oral cancer and natural history of oral precancerous lesions in a 10-year follow-up study of Indian villagers. *Community Dent Oral Epidemiol* 1980; 8(6):283–333.
- Pearson N, Croucher N, Marcenes W, O'Farrell M. Prevalence of oral lesions among a sample of Bangladeshi medical users aged 40 years and over living in Tower Hamlets, UK. *Int Dent J* 2001; 51(1):30–4.
- Marx RE, Stern D. *Oral and maxillofacial pathology. A rationale for diagnosis and treatment*. Quintessence Publishing Co, Inc.; 2003. p. 317–9.
- Sylvie Louise Avon. Oral mucosal lesions associated with use of quid. *J Can Dent Assoc* 2004; 70(4): 244–8.