

Residual Ridge Resorption in Complete Denture Wearers

Samyukta,

Student- BDS Second Year, Saveetha Dental College

Dr. Abirami G,

Department of Prosthodontics, Saveetha Dental College

INTRODUCTION:

In naturally dentate species, the teeth, jaws, and oral mucosa are not static objects; they are dynamic (changing over time) and hence, edentulism is much more than just the simple presence or absence of teeth and biochemically complex processes such as bone remodeling (loss and gain of bone tissue) in the jaws are clinically important for edentulous people.

A.R Tencate states that alveolar ridges are columns of bone of the maxilla and mandible that surround and anchor the teeth and run the entire length, mesiodistally. It is unique in that it houses and is present for the sake of the teeth that it retains; when the teeth are absent, the bone slowly resorbs. The maxilla resorbs in a superioposterior direction, and the mandible resorbs in an inferioanterior direction.

In addition, the alveolus also resorbs faciolingually, diminishing the width of the ridge. What initially began as a bell curve-shaped ridge (in the faciolingual dimension) eventually becomes a short, narrow, stump that does not even resemble a ridge.

Atewood (1971) described RRR as “MAJOR ORAL DISEASE ENTITY” characterised by loss of oral bone after the extraction of teeth. - The size, shape and tolerance of residual ridges provides the basis of stability, retention, support of complete denture.(1) Residual ridge resorption (RRR) is a term that is used to describe the changes which affect the alveolar ridge following tooth extractions, which continue even after healing of the extraction socket.(2)

GROSS FEATURES

a. Similarities

- With increased resorption or resorptive age, the mandible does not widen with the narrowing of the maxilla, nor there is a change in the posterior maxillomandibular width relations progressively.
- The arch width of the mandible exceeds the arch width of the maxillae in the molar region by an average of 6 to 7 mm after sufficient resorption established a definitive alveolar crest.
- The progressive and irreversible mandibular alveolar resorption is progressive and irreversible, with the rate being greatest in the early stages of edentulism and decreasing with loss of bone, longevity of edentulism, and attendant wearing of dentures.(3)

b. Differences

The speed and direction of alveolar bone loss is not similar in maxilla and mandible(Bergman & Carlsson, 1985;

Salonen, 1994). Faster and more dramatic changes take place in the mandible (de Baat *et al.*, 1993). In maxilla the changes occur evenly around the dental arch, but more on buccal and labial side than on the palatal side. In mandible resorption proceeds more in labio-lingual and vertical directions. Unlike in maxilla, the speed of bone loss in mandible is different in different parts of the jaw: distal parts of the residual ridge disappear faster than the anterior parts. Today, implant treatments are well-documented procedures to replace missing teeth or to provide retention for complete dentures. An early issued implant can even slow down the inevitable RRR. From the medical point of view there is limited contraindication for the use of osseointegrated implants (Oikarinen *et al.*, 1995), but the implant treatments are still too expensive for the majority of elderly.(4)

Differences in resorption can have effects which are limited to the alveolar process in the maxilla, rarely moving to its body, while in the mandible changes also affect the mandibular angle, leading to its atrophy. Alveolar loss in the maxilla runs from the cheek to the palate in the horizontal plane, in the mandible the alveolar ridge becomes atrophic in the glosso-buccal direction in its lateral parts, while in the anterior part this occurs from the oral vestibule [5]. According to Parkinson [6], an increase in the incidence of mandibular as opposed to maxillary resorption is more rapid in the initial edentulous period and decelerates as bone loss progresses; unfavourable consequences of toothlessness resulting in mastication impairment as well as loss of parodontal tissue receptors, which play a significant regulatory role in the function of the masticatory organ.

The anterior mandible resorbs 4 times faster than the anterior maxilla. The probable reason for this fact: the difference in the square area of the maxilla and the mandible, the feature of the mucoperiosteum as a ‘shock absorber’ and the variation in the quality of bone of the two jaws. Woelfel *et al* have cited the projected maxillary denture area to be 4.2 sq in and 2.3 sq in for the mandible; which is in the ratio of 1.8:1. If a patient bites with a pressure of 50 lbs, this is calculated to be 12 lbs/sq in under the maxillary denture and 21 lbs/sq under the mandibular denture. The significant difference in the two forces may be a causative factor to cause a difference in the rates of resorption. (Woelfel *et al*, 1974, 1976) The mucoperiosteum due to its ‘spongy’ nature has a ‘dampening effect’ on the forces that are transmitted to the alveolar ridge. Since the overlying mucoperiosteum varies

in its viscoelastic properties from patient to patient and from maxilla to mandible, its energy absorption qualities may influence the rate of RRR. Cancellous bone is ideally designed to absorb and dissipate the forces it is subjected to. The maxillary residual ridge is often broader, flatter, and more cancellous than the mandibular ridge. Trabeculae in maxilla are oriented parallel to the direction of compression deformation, allowing for maximal resistance to deformation. The stronger these trabeculae are, the greater is the resistance. These anatomical variations may result in the observed differences in the RRR of the upper and lower jaw.(7)

Radiographic findings

Tallgren (8) found that the mean reduction in ridge height of the mandible following tooth extraction was twice that of the maxilla during the 1st year period. The ratio of mandibular to maxillary resorption increased further, to approximately ratio of 4:1 after 7 years of edentulousness (9,10). The results of this study showed that the rate of resorption was almost twice more pronounced in the mandible than in the maxilla after the five-year period of complete denture wearing. The mandibular ridge is more likely to bear higher functional forces transmitted through the dentures than the maxillary ridge. The most likely reason is the smaller area and less advantageous shape of the lower basal seat. In regard to the less marked resorption of the maxillary alveolar ridge, the resistance offered by the hard palate to forces transmitted through the maxillary dentures to the denture bearing area may play an important part (8).

Histologic features

In the course of life continuous bone rebuilding occurs. In young and healthy individuals the process involves a relative balance between bone resorption and absorption, with the result that premature bone loss is not observed. In older people the life span and proliferation of osteoclasts is significantly decreased, which results in domination of the resorptive processes over osteogenesis.(11) Bone loss is considered to commence in humans at 35–40 years of age, after peak bone mass has been achieved, and the atrophic processes then continue with varying intensity, accelerating in perimenopausal women as compared to men [12, 13].

Residual Ridge Remodelling

Following tooth extraction, a cascade of inflammatory mediators is initiated, resulting in the organization of a blood clot which leads to the eventual closure of the extraction wound. The clot then undergoes organisation and is gradually replaced by granulation tissue towards the periphery and base of the alveolar socket. After a span of seven to ten days, new bone formation is evident, with osteoid matrix present as noncalcified bone spicules. Mineralization progresses from the alveolar socket base in a coronal direction and two-thirds of the socket is filled in approximately 5 to 6 weeks. (Schropp et al, 2003) The resorption of the residual alveolar ridges is a chronic, continuous, life-long catabolic process of bone remodelling. (7). The rate of reduction in size of the

residual ridge is maximum in the first three months and then gradually tapers off. (2).The bony remodelling that subsequently takes place occurs in two phases: an initial and fairly rapid phase that can be observed in the first 3 months and the subsequent slow, minimal yet continuous resorption. During the initial period there is new bone formation with loss of almost all of the alveolar crest height and simultaneous reduction of approximately two-thirds of the ridge width. These changes continue over the initial ten to twelve week period. Between six and twelve months, part of the new laid-down bone undergoes further remodelling resulting in the further reduction of the alveolar ridge width until it is reduced to approximately half. The rate of resorption then slows down to minimal levels and continues throughout life, resulting in loss of varying amounts of jaw structure, finally leaving the patient a 'dental cripple'. This unique phenomenon is known as residual ridge resorption (RRR). The rate of RRR differs from person to person and even at different times and sites in the same person and also affects the function of removable prostheses, which relies greatly on the quantity and the structure of jaw bones.(14) Residual ridge reduction is one of the main causes of loss of stability and retention of mandibular complete dentures. The key to successful denture therapy lies in precise execution of the treatment plan formulated by evaluation of a complete comprehensive history and through examination. Such a treatment plan must be based on Devan's principles concerned with rehabilitation that is, preservation of what already exists than the mere replacement of what is missing. Ridge atrophy poses a clinical challenge towards the fabrication of a successful prosthesis. Extreme resorption of the maxillary and mandibular denture bearing areas results in sunken appearance of cheeks, unstable and non retentive dentures with associated pain and discomfort.(15)

Pathogenesis of RRR(14)

Immediately following the extraction (order II), any sharp edges remaining are rounded off by external osteoclastic resorption, leaving a high well rounded residual ridge (order III). As resorption continues from the labial and lingual aspects, the crest of the ridge becomes increasingly narrow ultimately becoming knife-edged (order IV). As the process continues, the knife-edge becomes shorter and even eventually disappears, leaving a low well rounded or flat ridge (order V). Eventually, this too resorbs, leaving a depressed ridge (order VI).

Functional effects of edentulism

The spatial relationship between the maxilla and the mandible is altered. there is a Progressive decreased in overall lower facial height, which leads to the characteristic overclosed appearance. conventional soft tissue – borne prosthetic devices become instable. Neurosensory changes secondary to atrophy occur in all three dimensions. Systemic factors.(16)

The factors that affect the RRR are still not completely elucidated. Studies describe involvement of 63 different factors and ridge resorption. (17-19) Devlin et al.(20)

suggest a series of factors that have categorized as systemic and local factors. The systemic factors include: a decrease in the absorption of calcium, systemic alterations such as osteoporosis, hyperthyroidism, hyperparathyroidism or diabetes, and certain medications such as corticoids or thyroxin, whose prolonged use constitutes risk factors for the onset of osteoporosis (21,22). On the other hand, the local factors include: the status of the alveolar process following the dental extraction (morphology, height and quality of the ridge), cause and type of dental extraction, extension and location of the tooth lost, duration of edentulism, stress on the ridge, parafunctions, antagonist and mucosa-supported prostheses. In addition to these local and systemic factors, the majority of the authors establish the age and sex of the patient as important factors in the resorption of the residual alveolar ridge (23,24). Findings of a study also showed significantly higher rate of RRR in patients who have been edentulous for a shorter period of time (<1 year, 1–10 years) prior the new denture delivery. (25)

Etiological Factors of Reduction of Residual Ridges

Atwood first postulated the four main factors namely anatomic, prosthetic, metabolic, and functional factors that are responsible for the loss of alveolar bone. (Atwood, 1957, 1962) Since then, numerous investigators have made an attempt to analyse the changes in the form of the residual alveolar ridge using lateral cephalograms, panoramic radiographs, or diagnostic casts as standardized measurements (Carlsson & Persson, 1967), the aim of these investigations being recognition of pathogenic/causative factor/factors, which is pending till date. (2)

Some Proposed Etiological Factors of Reduction of Residual Ridges(26) –

Anatomical Factors 1. More important in the mandible versus the maxilla, 2. Short and square face associated with elevated masticatory forces, 3. Alveoplasty.

Prosthetic Factors 1. Intensive denture wearing, 2. Unstable occlusal conditions, 3. Immediate denture treatment.

Metabolic and Systemic Factors 1. Osteoporosis, 2. Calcium and vitamin D supplements for possible bone preservation.

Resorptive pattern of the edentulous ridge (Mercier, 1995)

The ridge is wide enough at its crest to accommodate the recently extracted teeth. Type I – Minor ridge modelling.

The ridge becomes thin and pointed. Type II – Sharp atrophic residual ridge

The pointed ridge flattens to the level of the basal bone. Type III – basal bone ridge

The flattened ridge becomes concave as the basal bone resorbs. Type IV – basal bone resorption. (27)

Residual ridge form has been classified by Cawood and Howell as follows:

Class I – dentate

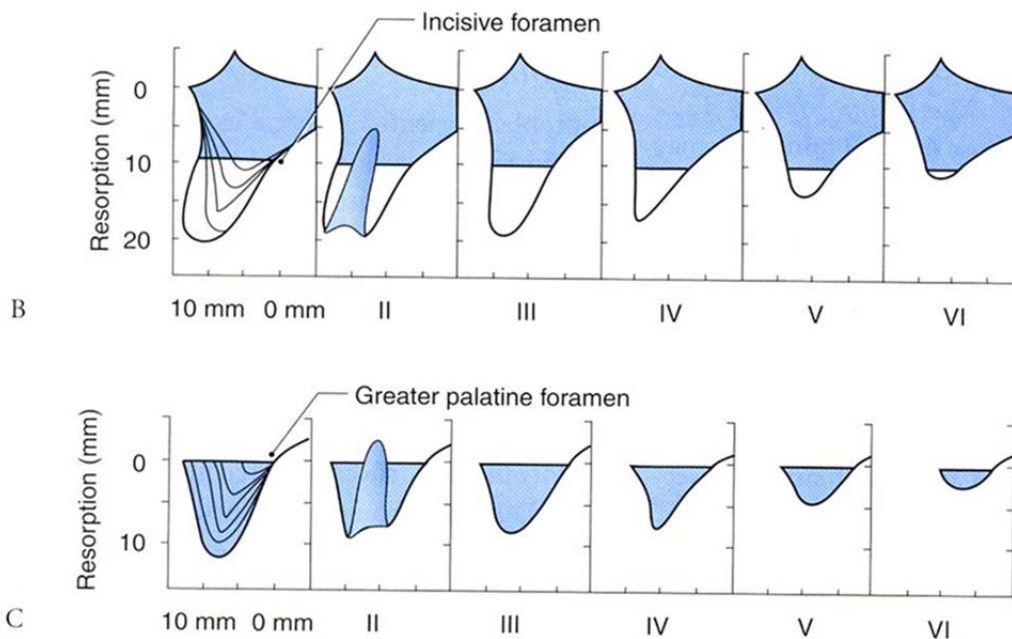
Class II – post-extraction

Class III – convex ridge form, with adequate height and width of alveolar process.

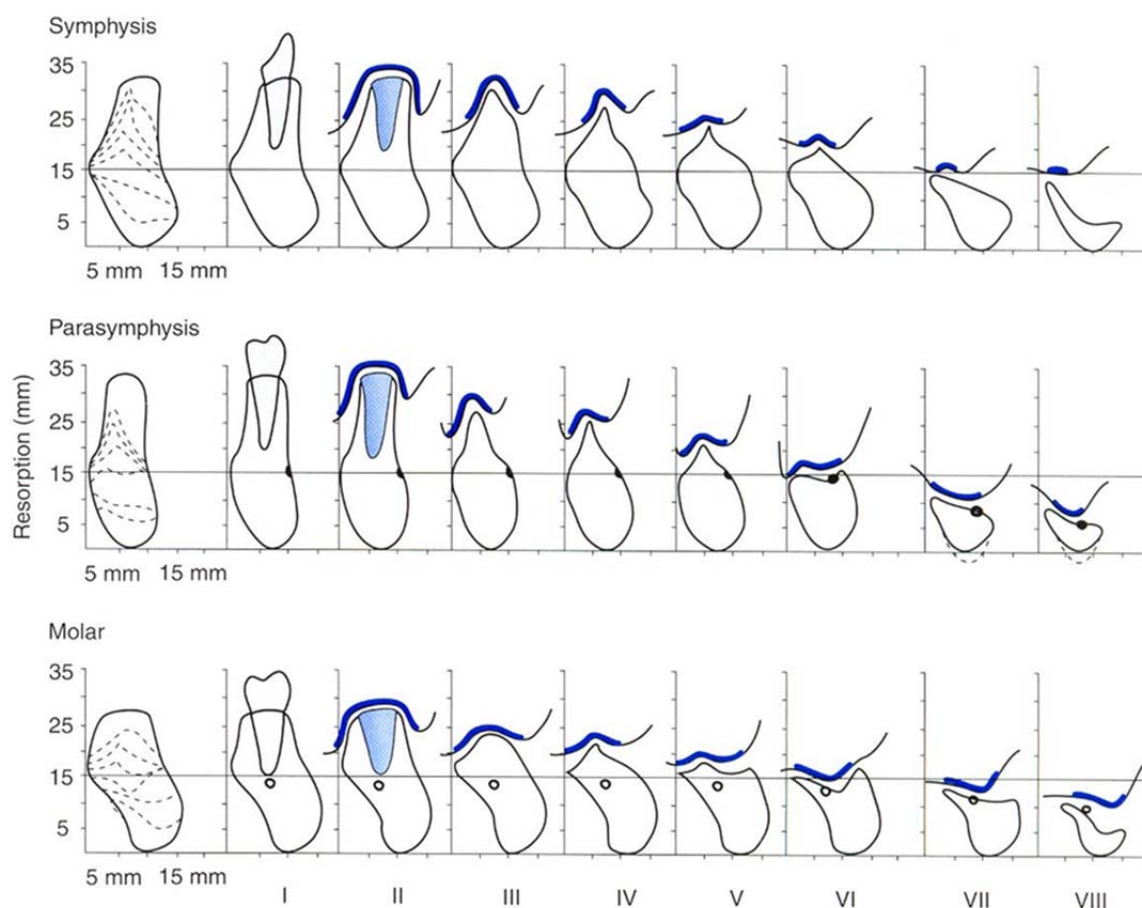
Class IV – knife edge form with adequate height but inadequate width of alveolar process.

Class V – flat ridge form with loss of alveolar process.

Class VI – loss of basal bone that may be extensive but follows no predictable pattern.(28)



Maxillary horizontal measurements (A). Classification of resorption of maxillary alveolar ridge: anterior (B) and posterior (C). Adapted from Cawood JI, Howell RA.⁷



Modified Cawood and Howell classification of resorption. The thicker line illustrates the amount of attached mucosa, which decreases with progressive resorption. Adapted from Cawood JI, Howell RA.⁷

In a study group, On the basis of radiological analysis of pantomograms (as described by Wical and Swoope, modified by Ortman) a resorption index (IC//IM) was calculated, it was found that the duration of mandibular edentulism was associated with the value of the radiological IC/IM index, which defines the grade of mandibular residual ridge resorption and the percentage mandibular bone loss in edentulous patients. IC is the distance between the inferior ridge of body of the mandible and the ridge of the alveolar part adjacent to the mental foramen and IM is the distance between the lower ridge of the mandible body and the inferior margin of the mental foramen. Classes of mandibular residual

ridge resorption were established on the basis of IC/IM index value. Results for IC/IM index > 2.34 were classified as mild resorption (class I), those ranging between 1.67 and 2.33 were defined as a moderate grade of resorption (class II) and values for IC/IM index < 1.66 were considered to represent a severe grade of resorption (class III). The IC/IM index was similarly used to assess the percentage of bone mass atrophy in each patient. The total calcium serum level was shown to correlate positively with the value of IC/IM index in edentulous patients.(29)

Assessment of RRR

Mandibular RRR was assessed by using the mental foramen and the inferior border of the mandible, as they appear in OPGs, as reference points using Wical and Swoope Analysis method; in which the original height of the mandible is assumed to be three times the distance between the inferior border of the mandible to the lower border of the mental foramen [Wical & Swoope (1974), Atwood (1996)]. The amount of mandibular ridge resorption (R) was estimated from the original mandibular alveolar level to the measured level of the residual ridge (L) was expressed as a per-centage of the original height of the mandible. The amount of resorption was calculated according to the formula: $R=3x-L$, (where R: amount of mandibular RRR; x: distance from inferior border of mandible to the lower border of mental foramen; L: height of mandibular residual alveolar ridge). The measuring error was set to ± 0.01 mm for specific measured dimensions on each OPG. Measurements were performed on the right side, and the mean value and standard deviation were calculated. The amount of mandibular RRR was calculated and correlated with duration of wearing complete dentures. Gender and age differences were also investigated and correlated to RRR and duration of complete denture wearing.(27)

Prosthetic Principles To Reduce RRR (Manish et al,2015)(30)

In order to preserve the alveolar ridge and reduce the amount of stress transferred, certain general principles must be kept in mind during fabrication of complete denture. This may be achieved by having broad area of coverage under the denture base (to reduce the force per unit area). A decrease in the number of denture teeth; decrease in the buccolingual width of teeth; improved occlusal tooth design form (to decrease the amount of force required to penetrate a bolus of food) are some of the other techniques that may also be used.(31) During tooth setup the aim should be to reduce the number of inclined planes (to minimize dislodgement of dentures and shear forces) and achieve a centralization of occlusal contacts (to increase stability of dentures and to maximize compressive load). Accurate recording of maxillomandibular relationship will ensure optimum vertical rest dimension which will decrease the frequency and duration of tooth contacts, thereby giving adequate rest to the underlying ridges (Kapur & Soman, 1964; Van Waas, 1990). (32)

Over the years complete tissue-supported removable prostheses have been regarded as the treatment of choice for edentulous patients. The main reason for this was the need of a more effective alternative. In spite of all the controversy, for the appropriate age and oral condition, general health, and socioeconomic status, a carefully fabricated complete removable denture may be a safe, predictable, and cost-effective treatment to restore an edentulous patient, especially in developing countries.

Implant supported overdentures

The field of prosthetic rehabilitation has been irreversibly transformed with the advent of osseointegrated titanium implants. The predictable clinical success of osseointegrated implants has ensured that the concept of an implant-supported prosthesis as a reliable protocol in the management of complete edentulism is now accepted world-wide. In the developed countries a mandibular 2-implant retained overdenture treatment modality is, by and large, considered the 'gold standard' for the treatment of the edentulous mandible. This is based on the efficacy of this treatment modality as regards function, nutrition, and overall quality of life, balanced with patient preferences and expectations, treatment planning, prosthetic management, and predicted costs. In lesser developed nations, however, the cost factor for such treatment over conventional dentures appears to be the only area of concern regarding its acceptability among all practitioners. With the increasing competition and marketing strategies adopted by the implant manufacturers, the cost of such implants will be sufficiently lowered for them to become affordable across the economic spectrum of patients. This will make implant supported prostheses a realistic option to rehabilitate all patients with poor ridges effectively and economically.(33)

REFERENCES:

- Atwood D.A., 1971. "Reduction of residual ridges : A major oral disease entity". *J. Prosthet. Dent.*, 26 : 266-279
- Derek D'Souza Oral Health Care – Prosthodontics, Periodontology, Biology, Research and Systemic Conditions
- Similarities in resorption patterns of maxillary and mandibular ridges. *J Prosthet Dent.* 1978 Jun;39(6):598-602
- Martti Juha Nevalainen; Academic Dissertation; Prosthetic Rehabilitation Of Missing Teeth And Oral Health In The Elderly; Helsinki on June 11, 2004,Page 15.
- Majewski S (2000) Podstawy protetyki w praktyce lekarskiej technice dentystycznej. Wydawnictwo Stomatologiczne SZS-W, Kraków.
- Parkinson CF (1978) Similarities in resorption patterns of maxillary and mandibular ridges. *J Prosthet Dent*, 39: 598–602.
- Derek D'Souza Prosthodontics India Residual Ridge Resorption – Revisited Differential resorption rate in maxilla and mandible
- TALLGREN A, *J Prosthet Dent*, 27 (1972) 120.
- TALLGREN A, *Acta Odontol Scand*, 25 (1967) 563.
- TALLGREN A, *Acta Odont Scand*, 27 (1969) 539.
- E. Zmysłowska et al., Mandibular residual ridge resorption, *Folia Morphol* Vol. 66, No. 3, pp. 346–352
- Pluskiewicz W, Rogala E (1995) Osteoporoz. Śląska Akademia Medyczna, Katowice.
- Włodarski K, Włodarski P, Brodzikowska A, Łuczak M, Galus K (1998) Starzenie się komórek osteogennych. *Czas Stomat*, 10: 631–638.
- Dr. AJAY GUPTA MDS, Dr. BHAWANA TIWARI, Dr. HEMANT GOEL MDS, Dr HIMANSHU SHEKHAWAT; Residual Ridge Resorption : A Review; © Indian Journal of Dental Sciences. All rights are reserved; Vol .2, Issue 2; March 2010; Pg # - 7
- Prosthetic Management Of Compromised Ridges And Situations Krishna Prasad D. , Divya Mehra & Anupama Prasad D. H.O.D & Professor, P. G. Student, Lecturer, Department of Prosthodontics and Crown & Bridge, A.B. Shetty Memorial Institute of Dental, Sciences, Nitte University, Mangalore, Karnataka, INDIA, *NUJHS Vol. 4, No.1, March 2014, ISSN 2249-7110*
- <http://www.intelligentdental.com/2011/11/26/ridge-augmentation/>
- WOELFEL JB, WINTERCH, IGARASHI T, *J Prosthet Dent*, 36 (1976) 602.
- KRIBBS PJ, CHESNUT CH, OTT SM, KILCOYNE RF, *J Prosthet Dent*, 62 (1989)703.
- KRIBBS PJ, SMITH DE, CHESNUT CH, *J Prosthet Dent*, 50(1983) 576. 13. DE BAAT C, KALK W, VAN HOF MA, *Community Dent Oral Epidemiol*, 21 (1993) 317.
- Devlin H, Ferguson MW. Alveolar ridge resorption and mandibular atrophy.A review of the role of local and systemic factors. *Br Dent J.* 1991;170:101-4.
- Xie Q, Ainamo A, Tilvis R. Association of residual ridge resorption with systemic factors in home-living elderly subjects. *Acta Odontol Scand.* 1997;55:299-305.
- Bras J. Mandibular atrophy and metabolic bone loss. *Int Dent J.* 1990;40:298-302.
- De Baat C, Kalk W, van 't Hof M. Factors connected with alveolar bone resorption among institutionalized elderly people. *Community Dent Oral Epidemiol.*1993;21:317-20.
- Klemetti E. A review of residual ridge resorption and bone density.*J Prosthet Dent.* 1996;75:512-4.
- Kovacic et al.: Decreasing of Residual Alveolar Ridge Height, *Coll. Antropol.* 34 (2010) 3: 1051–1056
- <http://www.slideshare.net/indiandentalacademy/sequelae-of-wearing-cd-rajat>
- Osama Al-Jabrah , Yousef Al-Shumailan, *International Journal of Dental Research Journal* home page: www.sciencepubco.com/index.php/IJDR, doi: 10.14419/ijdr.v2i1.1669
- <http://www.intelligentdental.com/2011/11/26/ridge-augmentation/>
- E. Zmysłowska et al., Mandibular residual ridge resorption, *Folia Morphol* Vol. 66, No. 3, pp. 346–352
- Manish K, Vinod K, Ravi G, Deepak M. Residual ridge resorption: a review. Manish et al, *GCC Journal of Science and Technology* 2015; 1(4):124-128
- Pendleton EC. Changes in the denture supporting tissue. *JADA* 1951; 42: 11-15.
- Lammie GA. Aging Changes and the complete lower denture. *J Prosthet Dent* 1956; 6: 450-464.
- Derek D'Souza ProsthodonticsIndia Residual Ridge Resorption – Revisited Prosthetic rehabilitation of resorbed ridges - Conventional complete dentures