

# Prevalance of Linea Alba Buccalis in Chennai Population

Sharmila.R

Saveetha Dental College, Chennai

## Abstract

**Aim:** The aim of this study is to determine the prevalence of linea alba buccalis in chennai population.

**Objective:** To study the prevalence of frictional keratosis among the different age groups with and without parafunctional habits.

**Background:** Linea alba buccalis is a thickened whitish line on the buccal mucosa at the level of the occlusal plane extending from the corners of the mouth to the posterior teeth. It is usually associated with the frictional activity of the teeth and may be accentuated by cheek biting or parafunction. The appearance is caused by a keratosis of the epithelial tissue which cannot be rubbed off. It is asymptomatic and is usually present bilaterally. Linea alba buccalis is frequently associated with a cremated tongue which may be a sign of bruxism. The condition does not require treatment.

**Reason:** Linea alba buccalis being common finding, it may also be found in individuals who chew tobacco, a thorough analysis of the prevalence along with the various contributing factors would assist in prompt treatment and prevent further complications.

## INTRODUCTION

The oral cavity is considered as a mirror of general health. Mucosal lesions may be discovered during routine dental examinations and vary depending on age, gender and /or race. Majority of oral diseases are confined to oral tissues, but numerous underlying systemic conditions may manifest with signs and symptoms within the oral cavity(1). Linea alba is a raised, white line usually along the inside of the cheek. It occurs as a result of clenching or biting the inside of one's cheek. It is a very common finding and it is most likely associated with pressure, frictional keratosis, or suction trauma from the facial surfaces of the teeth. It is usually present bilaterally and may be pronounced in some individuals. These white lines may disappear spontaneously in some people(2). In a Turkish study among adolescents (13-16 years of age) linea alba was the second commonest finding which accounts for 5.3% of the total (3). It is believed that parakeratosis occur along the line of the occlusal plane as the cheeks suck in due to the negative pressure (4). Linea alba is asymptomatic and generally considered a normal variation than pathological (5) and therefore, no treatment is required.

The present study was undertaken to highlight the prevalence of Linea alba in chennai population and to bring out awareness among the patient in the saveetha dental college.

## MATERIAL AND METHODS

The present study was conducted on new patients attending the saveetha dental college between December 2015 and April 2016. Informed consent was obtained from patients participating in the study.

A screening examination including intraoral clinical exam using artificial light, dental mirror, dental explorer, gauze, and other materials as described (Al-Mobeeriek and Al-Dosari, 2009, Byakodi et al., 2011 and Campisi and

Margiotta, 2001). Personal data including age, gender and social habits were recorded.

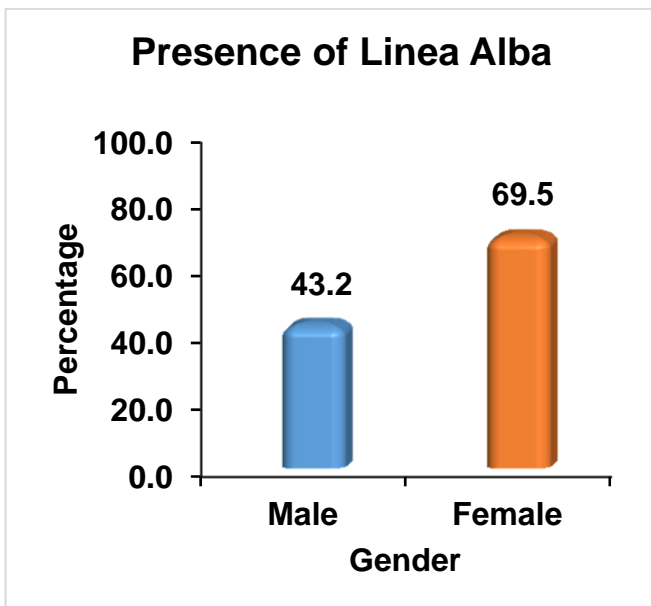
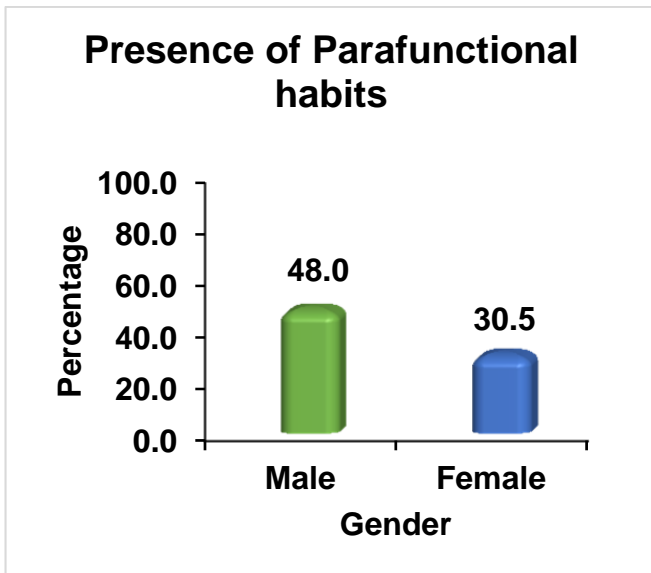
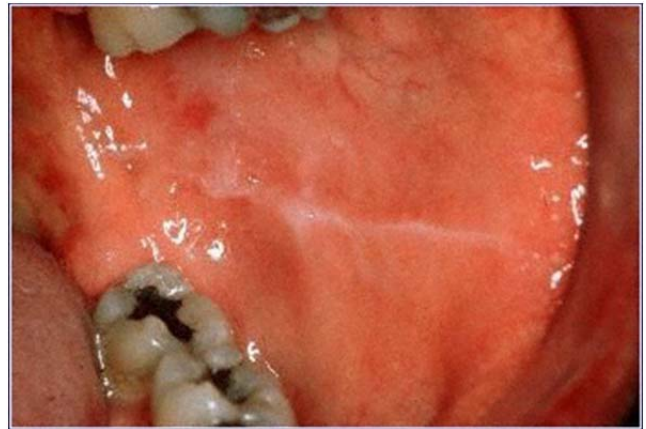
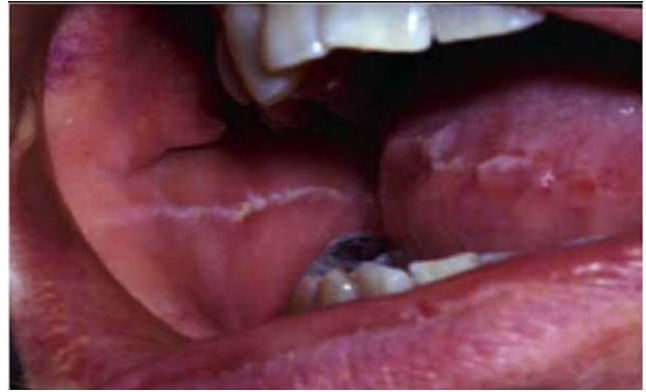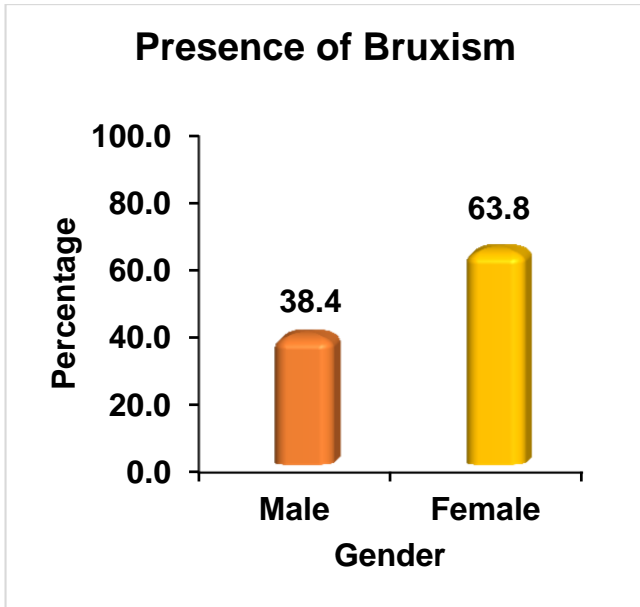
Data were analyzed using the chi square (Statistics) to compare the prevalence of the linea alba based on the characteristics of age, gender, tobacco use, alcohol use and bruxism. A p value of  $\leq 0.05$  was considered statistically significant.

## RESULTS

Linea Alba	Gender						P-Value
	Male		Female		Total		
	N	%	N	%	N	%	
Present	54	43.2	73	69.5	127	55.2	<0.001
Absent	71	56.8	32	30.5	103	44.8	
Total	125	100.0	105	100.0	230	100.0	

Bruxism	Gender						P-Value
	Male		Female		Total		
	N	%	N	%	N	%	
Present	48	38.4	67	63.8	115	50.0	<0.001
Absent	77	61.6	38	36.2	115	50.0	
Total	125	100.0	105	100.0	230	100.0	

Parafunctional habits	Gender						P-Value
	Male		Female		Total		
	N	%	N	%	N	%	
Present	60	48.0	32	30.5	92	40.0	0.007
Absent	65	52.0	73	69.5	138	60.0	
Total	125	100.0	105	100.0	230	100.0	



#### DISCUSSION

In previous reports, prevalence rates for linea alba have shown wide variation, and may be a function of underlying differences in the geographic areas studied, socio-demographic characteristics of the examined population, the research methodologies used, and the diagnostic criteria employed. Linea alba, a normal variation of oral mucosa, is described as a slightly raised, usually bilateral, whitish line traversing the corner of the mouth as far posterior as the last molar tooth(6). In the current study, linea alba was the most common finding with a prevalence rate of 7.8%. Parlak et al. reported it to be the second most common lesion in Turkish adolescents, with a prevalence of 5.3% (7).

Linea alba was seen in 4.80%. It was highly significantly more common among females (5.86%) than in males (3.64%). This prevalence is comparable to the finding by Cebeci et al. (8) in Turkey (4.2%), but it is lower than that found by Martinez and Garcia pola [10.1%] (9).

In our study total of 230 patients were included, in which 125 were males and 105 were females. Among the 125 males 54 (43.2%) were diagnosed with linea alba. 38.4% of the males were known to have bruxism habits and 48.0% of the males have parafunctional habits.

Among the 105 females 73 (69.5%) were diagnosed with linea alba. 63.8% of the females were known to have bruxism habits and 30.5% of the females have parafunctional habits.

Compared to other studies which have been done previously regarding the prevalence of linea alba, more number of adults within the age group 20-46 are known to have Linea alba than the children, among which female

predilection is more. Linea alba maybe used to evaluate the severity of bruxism. A thickened whitish line on the buccal mucosa at the level of the occlusal plane extending from the corners of the mouth to the posterior teeth. It is usually associated with the frictional activity of the teeth and may be accentuated by cheek biting or parafunction. The appearance is caused by a keratosis of the epithelial tissue which cannot be rubbed off. It is asymptomatic and is usually present bilaterally. Linea alba buccalis is frequently associated with a crenated tongue which may be a sign of bruxism. The condition does not require treatment.

#### CONCLUSION

There are derarth any studies regarding the the prevalence of linea Alba buccalis in the chennai population. Hence, the present study is conducted to determine the prevalence of linea Alba buccalis in chennai population. In this context, this study is an important addition to the existing literature. In the present research, the prevalence of linea alba buccalis is more common among the adults particularly females associated mostly with bruxism. This study highlights the need for few community awareness health programs at a larger scale. Hence, mass screening should be done to ensure early detection and prompt treatment of the various oral diseases.

#### REFERENCE

1. Jones AV, Franklin CD. An analysis of oral and maxillofacial pathology found in children over a 30-year period. *Int J Paediatr Dent.* 2006; 16: 19-30.
2. Bhattacharyya I, Cohen DM, Jr Silverman S. Red and white lesions of the oral mucosa. In: Greenberg MS, Glick M, editors. *Burket's oral medicine.* 10th ed. Hamilton: BC Decker; 2003. p.85-125.
3. Parlak AH, Koybasi S, Yavuz T, Yesildal N, Aydogan I, et al. Prevalence of oral lesions in 13 to 16 year old students in Duzce, Turkey. *Oral Diseases.* 2006; 12: 552-558.
4. Seoane LJM, Aguado SA, Varela-Centelles PI, Vazquez GJ, Romero MA, et al. Oral Mucosa: variations from normalcy, part I. *Cutis.* 2002; 69: 131-131.
5. Bhattacharyya I, Chehal HK. White lesions. *Otolaryngologic Clinics of North America.* 2011; 44: 109-131.
6. Seoane Leston JM, Aguado Santos A, Varela-Centelles PI, Vazquez Garcia J, Romero MA, Pias Villamor L. Oral mucosa: Variations from normalcy, partI. *Cutis.* 2002; 69: 131 – 134.
7. Parlak AH, Koybasi S, Yavuz T, Yesildal N, Anul H, Aydogan I, et al. Prevalence of oral lesions in 13 to 16-year old students in Duzce, Turkey. *Oral Dis.* 2006; 12: 553 – 558.
8. Cebeci AR İ, Gülşahi A, Kamburoğlu K, Orhan BK, Öztaş B. Prevalence and distribution of oral mucosal lesions in an adult Turkish population. *Med Oral Patol Oral Cir Bucal* 2009; Jun: 14 (6): E272-7.
9. Martínez AI, García-Pola MJ. Epidemiological study of oral mucosal pathology in patients of the Oviedo School of Stomatology. *Med Oral* 2002; 7(1): 4-16.