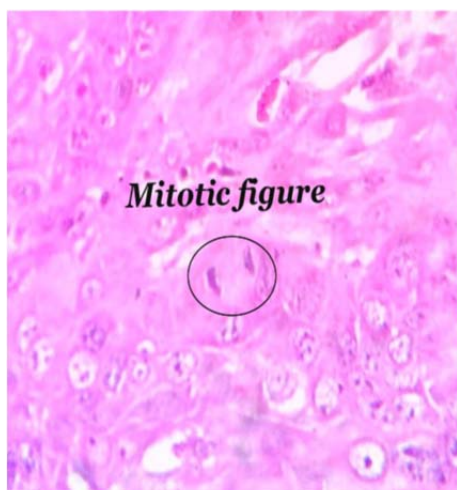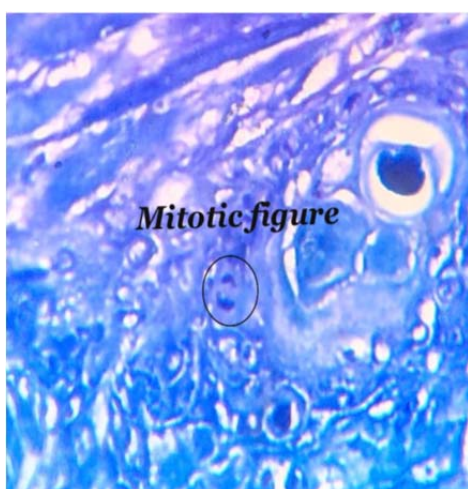


H &amp; E stain



Toluidine blue stain

#### DISCUSSION:-

Dysplasia is associated with altered tissue architecture including cellular proliferation leading to the malignant transformation if left untreated<sup>5</sup>. Mitotic figures is one of the reliable criteria to assess dysplasia. Mitotic figures should be carefully evaluated to assess cellular proliferation. H & E stain and Toluidine blue stains have been used over decades to stain mucosal lesions. H & E is the most widely used histologic stain due to its easy availability. It shows most of the histologic structures but sometimes differentiation of mitotic figures maybe difficult. This is when alternate special stains like Toluidine blue are indicated. Toluidine blue has metachromatic property and stains acidic components and hence it has been used to stain mitotic figures. It is based on the fact that dysplastic cells may contain more nucleic acids than normal cells. The high density of nuclear material, loss of cohesion and increased mitosis maybe the reason for the easy uptake of Toluidine blue stain by the dysplastic cells<sup>6</sup>. Lingen *et al*, in their review mentioned the sensitivity and

specificity of TB in the detection of oral cancer to be in the range of 78-100% and 31-100%, respectively<sup>7</sup>. Epstein *et al* showed sensitivity and specificity of 92.5% and 63.2%, respectively in their results<sup>8</sup>. Another study found 100% sensitivity and 52% specificity<sup>9</sup>. Onofre *et al* evaluated the TB staining in pre malignancies and superficial oral ulceration suggesting malignancy and 100% sensitivity with no false results<sup>10</sup>. Hedge *et al* found a sensitivity of 97.29% and specificity of 62.5%<sup>11</sup>. Gupta *et al* demonstrated sensitivity of 96.9% and specificity of 86% for detection of malignancy using TB<sup>12</sup>. The results of our study in relation to the no.of mitotic figures observed was in accordance with the previous studies conducted.

#### CONCLUSION:-

H & E and Toluidine blue stains stain the dysplastic tissues. Being a metachromatic, acidophilic vital stain, the mitotic figures are enhanced with the use of Toluidine blue stain.

#### REFERENCES:-

1. Kapoor K, Puri A, Prakash A, Jazib, Sharma G. Mitotic Counting and its Significance in Histopathological Grading of OSCC & Oral Epithelial Dysplasia. *Heal Talk*. 2013;5(6):35-37.
2. Palaskar SJ, Patil S, Narang B, Prabhu P, Kathuriya P, Pawar R. Efficacy of Various Stains to Study Mitotic Figures in Oral Epithelial Dysplasia – A Pilot Study. *Journal of Dental & Allied Sciences*. 2013;2(2):46-48.
3. Rao RS, Patil S, Agarwal A. Comparison and Evaluation of Mitotic Figures in Oral Epithelial Dysplasia using Crystal Violet and Feulgen Stain. *JCDP*. 2014;15(3):273-277.
4. Tandon A, Singh NN, Brave VR, Sreedhar G. Image analysis assisted study of mitotic figures in oral epithelial dysplasia and squamous cell carcinoma using differential stains. *JOBCCR*. 2016;6:S18-S23.
5. Sandhya T, Avinash T, Kesarkar K, Acharya S. Comparison of staining of mitotic figures by H and E and Crystal Violet stains in odontogenic tumours with aggressive behaviour – A preliminary study. *International Journal of Current Research*. 2016;8(6):32658-32662.
6. Sridharan G, Shankar AA. Toluidine blue: A review of its chemistry and clinical utility. *JOMFP*. 2012;16(2):251-255.
7. Lingen MW, Kalmar JR, Karrison T, Speight PM. Critical evaluation of diagnostic aids for the detection of oral cancer. *Oral Oncol*. 2008;44:10-22.
8. Epstein JB, Scully C, Spinelli J. Toluidine blue and Lugol's iodine application in the assessment of oral malignant disease and lesions at risk of malignancy. *J Oral Pathol Med*. 1992;21:160-3.
9. Epstein JB, Oakley C, Milner A, Emerton S, van der Meij E, Le N. The utility of toluidine blue application as a diagnostic aid in patients previously treated for upper oropharyngeal carcinoma. *Oral Surg Oral Med Oral Pathol Oral Radiol Endod*. 1997;83:537-47.
10. Onofre MA, Sposto MR, Navarro CM. Reliability of toluidine blue application in the detection of oral epithelial dysplasia and *in situ* and invasive squamous cell carcinomas. *Oral Surg Oral Med Oral Pathol Oral Radiol Endod*. 2001;91:535-40.
11. Hedge CM, Kamath PN, Sreedharan S, Dannana NK, Raju RM. Supravital staining: It's role in detecting early malignancies. *Indian J Otolaryngol Head Neck Surg*. 2006;58:31-4.
12. Gupta A, Singh M, Ibrahim R, Mehotra R. Utility of toluidine blue staining and brush biopsy in precancerous and cancerous oral lesions. *Acta Cytol*. 2007;51:788-94.