

Awareness of Oral Pigmentation and Lesions among Pre-Clinical Undergraduate Students-A Comparative Study

Dr. Brundha MP, MD, DNB,

Department of Pathology, Saveetha Medical college, Saveetha University

Abstract:**Aim:**

The aim of the study is to create awareness of oral pigmentation among preclinical undergraduate students.

Objective:

The purpose of the present study is to create the awareness of oral pigmentation among pre-clinical undergraduate students.

Background:

Oral pigmentation is a relatively common condition that may involve any portion of the oral cavity. Multiple causes are known, and they may range from simple iatrogenic mechanisms, such as implantation of dental amalgam, to complex medical disorders, such as Peutz-Jeghers syndrome. Local irritants, such as smoking, may also result in melanosis of varying degrees. Oral pigmented lesions result from cellular hyperplasia that can range from benign nevi to fatal oral melanoma. Pigmented entities may arise from intrinsic and extrinsic sources. The colour may range from light brown to blue-black. Melanin is brown, yet it imparts a blue, green, or brown colour. A precancerous lesion is "a morphologically altered tissue in which oral cancer is more likely to occur than its apparently normal counterpart." These precancerous lesions include leukoplakia, erythroplakia, and the palatal lesions of reverse smokers.

Reason: The present study is to create the awareness of oral pigmentation among the pre-clinical undergraduate students and to access the knowledge of the students.

Key Words: Leukoplakia, Melanin, malignant lesions, Amalgam pigment, smokers palate.

INTRODUCTION:

Oral pigmentation is a common condition involving the oral cavity. Peutz-Jeghers syndrome is an autosomal dominant disorder characterized by intestinal hamartomatous polyps in association with mucocutaneous melanocytic macules(1). Pigmented macules, often confluent and varying in size and shades of brown, appear in almost all cases periorally and on the lips and buccal mucosae. Any oral site may be involved, and the degree of pigmentation and oral involvement vary among affected individuals(2).

Melanotic macules may be solitary or multiple and can involve the gingiva, lip, as shown below, palate, buccal mucosa, and alveolar ridge, as shown below. Microscopically, this melanin deposit is mainly in the basal cell layers. Melanin may also be seen in the connective tissue near the basal cell layer. Oral nevi are uncommon in the oral cavity(3).

When they are present, they appear most commonly on the palate or gingiva. They can be intramucosal, junctional, compound, or blue nevi. Oral melanomas are uncommon, and, similar to their cutaneous counterparts, they are thought to arise primarily from melanocytes in the basal layer of the squamous mucosa. In contrast to cutaneous melanomas, which are etiologically linked to sun exposure, risk factors for oral melanomas are unknown(4).

Oral cavity cancer accounts for approximately 3% of all malignancies and is a significant worldwide health problem. Most oral malignancies occur as squamous cell

carcinomas (SCCs); despite remarkable advance in treatment modalities, the 5-year survival rate has not significantly improved over the past several decades and still hovers at about 50-60% (5). Many oral SCCs develop from premalignant conditions of the oral cavity. A wide array of conditions have been implicated in the development of oral cancer, including leukoplakia, erythroplakia, palatal lesion of reverse cigar smoking, oral lichen planus, oral submucous fibrosis, discoid lupus erythematosus, and hereditary disorders such as dyskeratosis congenital and epidermolysis bullosa(6).

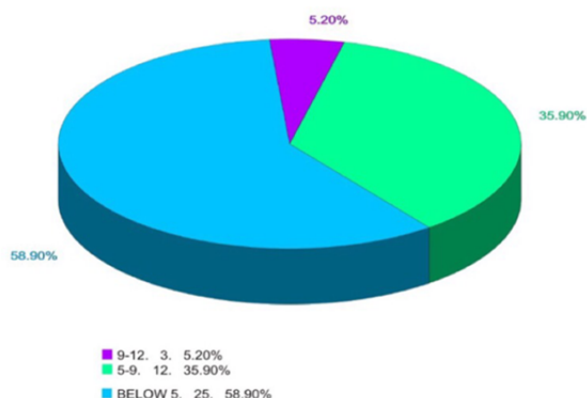
MATERIALS AND METHOD :

A template consisting of 12 various oral pigmentation and lesions was designed. The study was conducted in Saveetha dental college and hospitals in Chennai. Pre-training and post-training was given to preclinical undergraduate students to test their knowledge. The data was collected and analysed statistically.

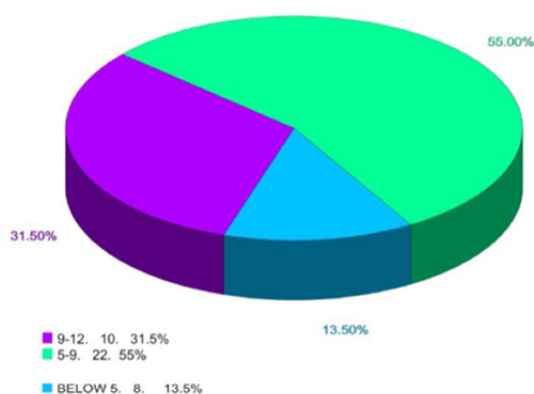
RESULTS :

During pre-training, most of the pre-clinical undergraduate students scored below 5 (58.90%). Only few scored between 5-9 (35.90%) and 9-12 (5.20%). This clearly depicts that they were not aware among the various oral pigmentation and malignant lesions. So, the training was conducted immediately. The post-training shows drastic improvement where most of them scored 9-12 (31.5%) and 5-9 (55%) and only few scored below 5 (13.5%). These results are shown in graph 1 and graph 2.

PRE TRAINING



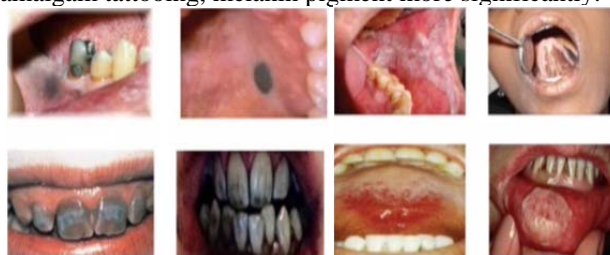POST TRAINING



DISCUSSION:

Oral pigmentations and malignant lesions are the ones which an individual should be aware of. The training was conducted to the subjects would have gained beneficiary knowledge regarding oral pigmentation and lesions (7). The photographic pictures were selected randomly based on most known to least known . During the pre training ,the most easily identifiable pictures among 12 were amalgam pigmentation, Melanotic nevi, Amalgam tattooing, Leukoplakia , Smokers palate, Tetracycline staining ,Carbon dust staining etc. In this during pre-training Amalgam pigment is mistaken as caries, Melanotic nevi is mistaken as mole in the mouth, Smokers palate is mistaken as red dots in mouth, Tetracycline staining is mistaken as black teeth.During post training, the students were able to

identify leukoplakia, carbon dust pigment, smokes palate ,amalgam tattooing, melanin pigment more significantly.



During post training 80% of the subjects were able to easily recognise most of the oral pigments and lesions(8) . Thus, the training was found to be effective,Though it is not statistically significant by doing in paired t –test .

CONCLUSION:

From the present study it is suggested that during pre-training most of the students were not able to find the oral pigmentation and lesions correctly from the given photographs .During post training there was an increase in scoring level of the students and most of the students were able to identify the oral pigmentation and lesions easily.Hence the training is said to be more effective and those pre- clinical students who enter into the clinical level they can identify the lesions and pigments in the oral cavity of the patients.

REFERENCES:

1. Çerman AA, Altuna IK. Oral pigmentation. *J Pigment Disorder*. 2016 Jan. 3:234.
2. Boardman LA, Thibodeau SN, Schaid DJ, Lindor NM, McDonnell SK, Burgart LJ, et al. Increased risk for cancer in patients with the Peutz-Jeghers syndrome. *Ann Intern Med*. 1998 Jun 1. 128(11):896-9.
3. Giardiello FM, Welsh SB, Hamilton SR, Offerhaus GJ, Gittelsohn AM, Booker SV, et al. Increased risk of cancer in the Peutz-Jeghers syndrome. *N Engl J Med*. 1987 Jun 11. 316(24):1511-4.
4. Eneroth CM, Lundberg C. Mucosal malignant melanomas of the head and neck with special reference to cases having a prolonged clinical course. *Acta Otolaryngol*. 1975 Nov-Dec. 80(5-6):452-8.
5. Jenne DE, Reimann H, Nezu J, Friedel W, Loff S, Jeschke R, et al. Peutz-Jeghers syndrome is caused by mutations in a novel serine threonine kinase. *Nat Genet*. 1998 Jan. 18(1):38-43.
6. Hussaini HM, Waddell JN, Girvan L, et al. Silver solder "tattoo," a novel form of oral pigmentation identified with the use of field emission scanning electron microscopy and electron dispersive spectrography. *Oral Surg Oral Med Oral Pathol Oral Radiol Endod*. 2011 Oct. 112(4):e6-10.
7. Lau JC, Jackson-Boeters L, Daley TD, Wysocki GP, Cherian MG. Metallothionein in human gingival amalgam tattoos. *Arch Oral Biol*. 2001 Nov. 46(11):1015-20.
8. Terezhalmay GT. Clinical images in oral medicine. Amalgam tattoos. *Quintessence Int*. 2006 Feb. 37(2):152-3.
9. S.Thaminee,Dr.Gheena.Oral lichen planus and its malignant transformation.2016 May.8(10),1226-1228.