



The Effect of Hydroalcoholic Extract of Watercress on Parameters of Reproductive and Sex Hormones on the Diabetic Rats

Jamshid Mohammadi^{1*}, Farideh Taheri Motlagh², Nasrin Mohammadi³

¹Associate Professor, Medicinal Plants Research Center, Department of Physiology, Yasuj University of Medical Sciences, Yasuj, Iran

²M Sc in Physiology, Department of Physiology, Islamic Azad University Fars Science & Research Branch, Fars, Iran.

³Medical student, Medicine School, Yasuj University of Medical Sciences, Yasuj, Iran

Abstract

It has been shown that many systems of the body like reproductive system are damaged by diabetes mellitus. The purpose of this research is to determine the effect of watercress (*Nasturtium officinalis*) on reproductive parameters and the rate of sex hormones after induction of diabetes in rats. Forty eight Wistar rats were used and divided into six groups of eight animals each. The groups I and II received distilled water. The groups III, IV and V received 250, 250 and 500 mg/kg body weight hydroalcoholic extract of watercress respectively. The group VI received 100 mg/kg of vitamin E. After twenty one day, the blood samples were collected of all rats to estimate serum levels of LH, FSH and testosterone. The testes were weighted and sperm was collected from the epididymis to analyze sperm count, morphology and motility. The results showed the mean of fast mobility increased significantly in groups V and VI compared to group III. Also the results of this study indicated, the rate of testosterone, LH and FSH increased in V and VI compared with the group III. Thus, from this study we concluded that hydroalcoholic extract of watercress could be improve the reproductive parameters and significantly increased sex hormones in diabetic rats.

Key words: Diabetes mellitus, Watercress, Sperm parameters, Rat, Testosterone

INTRODUCTION

The overall prevalence of infertility is approximately 8 - 10% of married. The infertility is a growing problem in the world and affects the lives of many couples. It is estimated that the rate of infertility between 50 to 80 million couples in worldwide [1]. Infertility and following complications are known as one of the most important issues for couples. Several items influence sperm making and are related to incidence of infertility. These factors include specific medication regimen, cancers, antibiotics, toxic compounds, radiation, stress, environmental pollutants and inadequate intake of vitamins [1]. The prevalence of infertility rates has increased the males all over the world. According to the published reports by researchers, each one of reasons can be the great effect of infertility in men. Histological observations revealed that many alterations in development of spermatogenesis such as diminishing of spermatozooids and congestion of interstitial tissue have been seen in diabetes mellitus [2, 3].

Vitamin E is a powerful antioxidant and its protecting role in sperm quantity and quality has frequently been reported. This vitamin causes the increase in sperm's living viability, by enhancing antioxidant capability. Vitamin-E deficiency induced oxidative stress reactions in testicular tissue and therefore reduces spermatogenesis and synthesis of testosterone [4, 5]. Herbal treatments are inherently safer, because uses traditional remedies rather than modern medicine. Utilizations of herbs can have positive effects on the increase of fertilization and elimination of issues such as sexual disability, low sperm count and low sperm mobility [6].

Watercress (*Nasturtium officinalis*), is a member of the *Brassicaceae* family, originated in central and western Europe but nowadays is spread all over the world [7]. It grows in different areas of Iran such as Tehran, Lorestan, Gilan, Fars, Kermanshah, kohgiluyeh and Boyer-Ahmad. This grass is long lasting with up-going stems that are quadrant and leaves that are periodic and feather like [8]. Watercress is full of several protecting vitamins and can be used in the treatment of metabolic and chronic diseases. At the end of 19th century, it was used for blood filtration and also pulmonary diseases [9]. Also, use of watercress has been reported to prevent cellular damage and elevate the level of antioxidant in the body [9-11].

Watercress is used in traditional medicine such as expectorant, appetizing and diuretic [12]. This plant has been recommended to be used for rheumatism, gout, disease of kidney, liver, tuberculosis, icterus and hypoglycemia [9, 13]. According to the complication of diabetes on testicular function, the main purpose of this research was to determine the effects of administration of hydro alcoholic extract of watercress for diabetic male rats on fertilization indexes and the rate of sex hormones.

MATERIALS AND METHODS

Plant Extraction

Aerial parts of Watercress plant was obtained from Cheram region and identified by the Department of Biology of Yasuj University, Yasuj, Iran. A voucher specimen has been deposited in the Medicinal Plants Research Center in Yasuj (MPRC -11). It's exsiccation was done under the air and shades, and then was floured by electrical pulverizer. 1000 ml of ethanol: water (70:30 ratios) was added by each

100 gr of the powder. The solutions were mixed by shaker for 24 hours at 20 to 24 centigrade degrees. The solvent was filtered by using a filter paper (Whatman No. 1). The solvent was removed in a rotary evaporator in vacuum at 57°C and dried for subsequent use. The resulting sample was powdered and sealed for subsequent use. Providing hydro alcoholic extract of watercress was done by rotary vacuum evaporator. The gained extract was kept at -20°C in freezer till the time of the experiment.

Experimental design

In this study, 48 Wistar rats (200-250 g) were obtained from animal laboratory of medical faculty. All experiments were performed according to the local ethical committee in YUMS, for use and care of animals by the code number 91.10.15.14. The animals were kept under the standard conditions based on ad libitum at room temperature $23 \pm 2^\circ\text{C}$ with a regular 12: 12 h L/D cycle. The animals were randomly divided into 6 groups of eight animals each. Groups I and II received 1ml distilled water and watercress hydroalcoholic extract (250mg/kg), respectively. Group III; diabetic control rats received 1 ml distilled water. Group IV; diabetic rats treated with watercress extract (250 mg/kg); Group V; diabetic rats treated with watercress extract (500 mg/kg); Group VI; diabetic rats treated with vitamin E (100 mg/kg). Animals in groups III, IV, V and VI were induced diabetic by a single intraperitoneal injection of streptozotocin (55 mg/kg dissolved in citrate buffer, PH=4/5). The extracts were prepared in dosages dosage of 250 and 500 mg/kg and dissolved in fresh distilled water. Administration of extract and distilled water was done by gavage method to all groups daily. One week after the induction of diabetes all rats treated daily for 21 days. Measurement of blood sugar was done by glucometer to ensure the occurrence of hyperglycemia. Experiments were daily performed for 21 days for all groups. At the end of the experimental period, rats were anesthetized by ether and their blood was taken by syringe. Blood specimens were kept at 37°C in the Laboratory for 30 minutes and were agglutinated for 10 minutes. The samples were subjected to centrifugation at 4000 rpm for 10 minutes. Samples were kept frozen in a -30°C degree freezer until the completion of the study. The animals were weighted end of the study. The testes were taken and recorded in all groups.

The relative organ weight was calculated according to organ weight/body weight $\times 100$. Through the use of Enzyme-Labeled Immunosorbent Assay (ELISA), serum concentration of testosterone was measured and expressed as ng/ml. FSH and LH were measured based on the Micro Plate the Enzyme-Labeled Immunosorbent Assay (ELISA) as described in the instructions provided by manufacturer's kits.

Methods of measuring sperm parameters

After anesthetizing, testis was taken out of scrotum. Then testis, cauda epididymides and sperm ducts were dissected. Next, testis were weighted with digital balance (A&C model, Korea) with sensitivity of 0/0001 gr. The semen (2 μl) was extracted from epididymis cauda by catheter. The semen immediately was diluted with normal saline (0.9% NaCl). The diluted sample was examined on lame and sperms were observed by their morbidity and morphology.

The achievement of sperms motility was observed under the light microscope with the 10X objectives. Average of these observations was reported as sperm motility. The account of sperm's mobility was divided into three forms of fast mobile, semi -mobile and none mobile. The neobar lam was used for counting sperms and their morphology. A drop of diluted sample was placed on lame and got counted very accurately. Sperm count and normal or abnormal morphologies were observed separately in square lines. Then for the measurement of sperm quantity the obtained numbers were multiplied by 10^6 .

Statistical analysis methods

The data were analyzed by statistical software SPSS (Version 21). The results were expressed as mean \pm standard deviation. One way ANOVA, T-test and turkey test were used for comparison of each parameter of each group. The significant value of each test was considered ($p < 0.05$).

RESULTS

Testicular weight

Figure 1 shows the changes of the relative weight of the testis in all groups. The relative weight of the testis with type 1 diabetes did not differ significantly across groups I, II, V, and VI, but there was a significant increase in the relative weight of the testis in group III ($P < 0.5$). The weight of testis decreased significantly in groups V and IV when comparing to group III.

Sperm parameters

The obtained results revealed that, the percentage level of mobile sperms in control group and control group treated with watercress extract was significant in comparison with diabetic control group. Also, the administration of 500 mg/kg watercress hydroalcoholic extract and vitamin E to V and IV groups caused a significant increase of mobile sperms in comparison with group III ($p < 0.05$) (Table 1).

The outcome has showed that, semi mobile sperms had a significant increase in group III in comparison with the groups I and II ($p < 0.05$). However, the administration of watercress hydroalcoholic extract and vitamin E to treated diabetic groups caused a significant decrease of semi mobile sperms in comparison with diabetic control group ($p < 0.05$). Results in Table 1 reveals that, none mobility was significantly higher in group III in comparison with the group I. Also administration of watercress hydroalcoholic extract and vitamin E to groups V and VI caused a significant reduction of none mobile sperms in comparison with group III ($p < 0.05$) (Table 1).

The results show, the sperm count show a significant difference between group III with groups I and II (Table 1). They, however, show a notable difference between treated diabetic groups with the diabetic control group. The sperm count of diabetic control group (93.7 ± 9.81) million shows a significant difference with diabetic group treated with 500 mg/kg of watercress extract group (133.7 ± 9.58) million ($p < 0.05$). Also comparison between diabetic group treated with vitamin E (128.6 ± 10.26) million and diabetic control group (93.7 ± 9.81) million shows a significant difference ($p < 0.05$).

TABLE 1. Effects of hydro alcoholic extract of watercress on sperm characteristics of control and experimental groups.

Group	fast mobile	semi –mobile	none mobile	Abnormal sperm rate (%)	Sperm count (million/ml)
Normal Control (I)	89.52 ± 8.44	9.35 ± 1.15	1.12 ± 0.16	10.83 ± 1.73	145.7 ± 17.38
Normal +250 mg/kg (II)	93.2 ± 5.28	4.08 ± 1.23	2.7 ± 0.64	12.54 ± 2.16	146.4 ± 15.65
Diabetic control (III)	52.88 ± 7.39*	26.55 ± 2.86*	20.55 ± 2.7*	41.87 ± 4.38*	93.7 ± 9.81*
D+250 mg/kg (IV)	73.63 ± 5.16 [¥]	14.19 ± 2.71	12.28 ± 1.42	38.44 ± 5.13	106.26 ± 14.22
D+500 mg/kg (V)	87.49 ± 4.27 [¥]	7.26 ± 1.34 [¥]	3.66 ± 0.35 [¥]	37.93 ± 2.56	133.7 ± 9.58 [¥]
D+vitamin E (VI)	95.17 ± 6.35 [¥]	3.2 ± 0.63 [¥]	1.61 ± 0.24 [¥]	33.01 ± 2.84 [¥]	128.6 ± 10.26 [¥]

The mean differences between the values ($p < 0.05$). Data are presented as mean ± SE. The asterisk symbol (*) indicates that $P < 0.05$ when comparing Group III to Group I. The yen symbol (¥) indicates that $P < 0.05$ when comparing Group V and VI to Group III.

TABLE 2. The effect of the hydro alcoholic extract of watercress on serum FSH, LH and testosterone of control and experimental groups.

Group	FSH (mIU/mL)	LH (mIU/mL)	Testosterone (ng/ml)
Normal Control (I)	0.47±0.12	1.21±0.138	1.60±0.091
Normal +250 mg/kg (II)	0.75±0.18	1.36±0.139	1.68±0.13
Diabetic control (III)	0.23±0.08*	0.85±0.152*	1.21±0.091*
D+250 mg/kg (IV)	0.39±0.09	1.06±0.316	1.49±0.349 [¥]
D+500 mg/kg (V)	0.63±0.15 [¥]	1.43±0.372 [¥]	1.64±0.387 [¥]
D+vitamin E (VI)	0.61±0.17 [¥]	1.25±0.53 [¥]	1.66±0.29 [¥]

The mean differences between the values ($p < 0.05$). Data are presented as mean ± SE. The asterisk symbol (*) indicates that $P < 0.05$ when comparing group III to group I. The yen symbol (¥) indicates that $P < 0.05$ when comparing treated groups to group III.

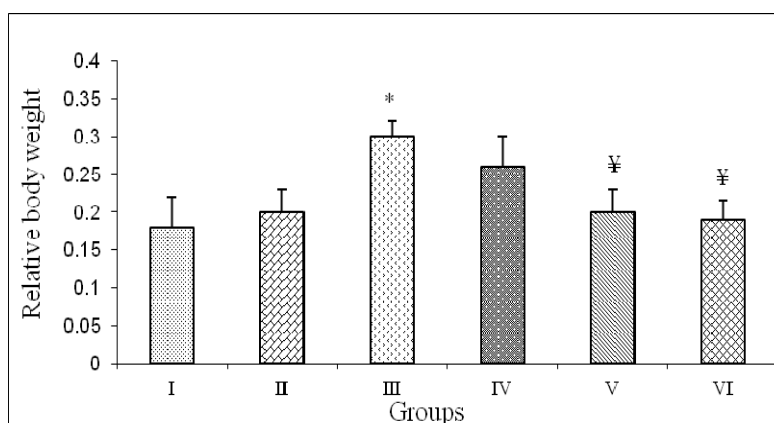


FIGURE 1. The vertical bars are showing mean values of testis weight (n=8). Lines above the bars indicate standard error (SE). The asterisk symbol (*) indicates that $P < 0.05$ when comparing Group III to Group I. The yen symbol (¥) indicates that $P < 0.05$ when comparing Group V and VI to Group III.

Statistical analysis revealed that, the abnormal morphology of sperms has been increased significantly in group III in comparison with groups I and II ($p < 0.05$) (Table 1). Administration of watercress hydro alcoholic extract to the V group shows decrease in abnormal morphology. Administration of vitamin E to the VI group shows significant decrease in abnormal morphology ($p < 0.05$). However, the administration of watercress hydroalcoholic extract in treated diabetic groups doesn't show any significant decrease when compared with the group III.

FSH, LH and testosterone hormones

There were significant increase in FSH levels at the dose of 500 mg watercress extract and vitamin E (V, VI groups) as compared with the group III (Table 2). Also the dose of 500 mg/kg watercress extract and vitamin E significantly increased LH level as compared with the diabetic control group ($p < 0.05$) (Table 2). The results revealed that the level of testosterone decreased in group III in comparison with groups I and II. Testosterone was elevated significantly in

treated groups in comparison with the group III. Further, results showed that by administration of vitamin E in the group VI, there was a significant increase in testosterone levels in comparison with group III ($p < 0.05$) (Table 2).

DISCUSSION

The results showed that the oral administration of watercress hydroalcoholic extract for 21 days in male rats led to improvement of rats' fertility as evidenced by significant increment of sperm cells number and sex hormones. Nowadays, extended studies are being done around the world on utilization of herbs for treatment of sexual disability. According to old books of traditional medicine, utilization of herbal medicine may have positive effects on sexual disability, low sperm count, slow mobility of sperms and inflammation of the prostate gland. Diabetes mellitus causes testicular tissue alternations by inducing apoptotic cell death, seminiferous tubule atrophies, decreasing the tubule's diameter and spermatogenic cells [14, 15]. Atrophy of seminiferous tubules and reduction of spermatogenic cells are morphological signs of spermatogenesis disorders [16]. It has been recognized that vitamin E is a potent biological antioxidant that is completely essential for the maintenance of spermatogenesis in mammals [16]. In normal condition, there are antioxidant agents in genital tissues and inhibit the appearance damage oxidative in gonad cell and adult spermatozoa [17, 18]. Researchers have demonstrated that vitamins E, C and B have been effective in reducing the toxic effects of cadmium on testicular tissues and the process of spermatogenesis [19]. Antioxidant functions of watercress have been proved due to existence of vitamin C in it [5]. Existence of these elements in watercress hydroalcoholic extract may have affected the partial improvement on indexes of sperm.

Recently some researchers reported, that diabetes mellitus can cause spermatogenesis dysfunction by mechanisms related to FSH and decrease the sperm count [2]. The quality of sperm fluid is significantly lower in diabetics with such symptoms as decrease of sperm mobility, sperm count and abnormal sperm shape [20]. The thickness of seminiferous tubule's basement membrane slows down the process of spermatogenesis and decreases sperm production [20, 21]. Moreover, there is a positive correlation between tubular diameter and spermatogenic function [22]. Previously reported that, neuroendocrine damage caused by diabetes, happens in hypothalamus, which controls hormonal function [18, 24]. Therefore, there might be some other factors that perturb insulin secretion which cause the incidence of diabetes [18].

According to the previous studies, administration of exogenous GnRH to diabetic rats is followed by elevation of pituitary gonadotropins and will have increase testosterone levels [23, 25]. Considering the dependence of sperms' growth and differentiation and their count on androgenic hormone level and watercress hydroalcoholic extract, cause improvement of hormone balances. Therefore it is possible that the hydroalcoholic extract of watercress is effective on hormones associated with the sperm indexes.

Manach and his colleagues reported that diabetes cause the decrease of sertoli cells, followed by the decrease of germ cells. The size of testicle is highly dependent on the amount of sertoli cells and sperm making, in a way that testicle size reflects the amount of germ cells in it [26]. It is reported that the spermatogenic function of men during puberty is based on the number of existent sertoli cells in testicular tissue [27]. The proliferation of sertoli cell is limited to pre-puberty ages, thus diabetes can have significant effects on testicular tissue. Khaki and his colleagues reported that, the extract of plants such as onion and ginger cause improvement of sperm indexes by having flavonoid antioxidant compounds, vitamins and Quercetin [27]. Antioxidant has protecting role on body's tissue and decreases the amount of free radicals [28].

Result of the research showed that, the administration of vitamin E to group VI caused a significant increase in mobile and count sperms when compared to group III (Table 1). Vitamin E is a potent hydrophobe antioxidant which is essential for keeping of spermatogenesis in mammals. Vitamin E increases the living capability of sperm by boosting the antioxidant system. The decrease of Vitamin E results in oxidative stress of testicular tissue and therefore reduces synthesis of testosterone and spermatogenesis. Former studies also revealed that it cause a decrease in lipid peroxidation damage [29, 30]. Therapeutic effects on testicular tissue showed that vitamin E, as an antioxidant, has the ability to rebuild seminiferous tubules after damages induced by ozone gas, reduce its damaging effects on testicular tissue and enhancing blood-testicular-barrier [31].

Results of this study show that the number of abnormal sperms decreased in treated groups compared with diabetic control group (Table 1). In addition, the administration of watercress hydroalcoholic extract partially increased sperm indexes in group II in comparison to group I. This demonstrates the sperm index's effects of antioxidant feature of watercress on the improvement of sperm indexes. Researchers have discovered that, oxidative stress reduces the level of enzymatic or non-enzymatic antioxidant in leydig cell and subsequently reduces the synthesis and secretion of testosterone [14, 31, 32]. Also oxidative stress is an effective item in spermatogenesis disorders and it, therefore, significantly decreases epididymal sperm count [14, 33]. In this research, a significant decrease of sperm count was seen in diabetic control group compared with normal control group. We suggested that the existence of flavonoids and some other antioxidants in watercress hydroalcoholic extract is able to reduce the symptoms of diabetes mellitus and improve sperm indexes near to normal [34].

CONCLUSION

According to the results suggest that the administration of watercress hydroalcoholic extract may increase sex hormones levels and improve sperm indexes by affecting spermatogenic and sertoli cells, due to existence of its chemical compounds. Further studies are underway to define the precise mechanism of protection mediated by watercress.

CONFLICT OF INTERESTS

The authors declare that they have no conflict of interest.

ACKNOWLEDGMENTS

This research is outcome of thesis of student; Farideh Taheri Motlagh, entitle: The effect of hydroalcoholic extract of Watercress on parameters of reproductive and sex hormones on the diabetic rats, which has been done at Medicinal Plants Research Center of Yasuj University of Medical Sciences. The authors would like to thank Yasuj University of Medical Sciences for support and extending facilities.

REFERENCES:

- [1]. Boivin J, Bunting L, Collins JA, Nygren KG. International estimates of infertility prevalence and treatment seeking: potential need and demand for infertility medical care. *Hum Reprod.* 2007;22:1506 - 1512.
- [2]. Ballester J, Munoz MC, Dominguez J, Rigau T, Guinovart JJ, Rodriguez-Gil JE. Insulin dependent diabetes affects testicular function by FSH-and LH-linked mechanisms. *J Androl.* 2004;25: 706-719.
- [3]. Mohammadi J and Naik PR. The histopathologic effects of *Morus alba* leaf extract on pancreas of diabetic rat. *Turk J Biol.* 2012; 36: 211-216.
- [4]. Mozdarani H, Salimi M. Numerical chromosome abnormalities in 8-cell embryos gamma-irradiated male mice in the absence and presence of vitamin E. *Int J Radiat Biol.* 2006;82:817-22.
- [5]. Nouri M, Ghasemzadeh A, Farzadi L, Shahnazi V, Ghaffari Novin M. Vitamins C, E and lipid peroxidation levels in sperm and seminal plasma of asthenoteratozoospermic and normozoospermic men. *Iran J Reprod Med.* 2008;6: 1-5
- [6]. Amr A, Alaa E, Hamza A. Effects of Roselle and Ginger on cisplatin-induced reproductive toxicity in rats. *Asian J Androl.* 2006; 8: 607-612.
- [7]. Biddington NL, Ling B. The germination of watercress (*Rorippa nasturtium-aquaticum*) seeds. I. The effects of age, storage, temperature, light and hormones on germination. *J Hort Sci.* 1983; 58: 417-426.
- [8]. Jafari S, Hassandokht M. Evaluation of some Iranian watercress (*Nasturtium officinale* L.) populations using agro-morphological traits. *Int J Forest, Soil and Erosion.* 2012; 2:119-123.
- [9]. Shahrokhi N, Khaksari Hadad M, Keshavarzi Z, Shabani M. Effects of aqueous extract of watercress on glucose and lipid plasma in streptozotocin induced diabetic rats. *Pak J Physiol.* 2009; 5: 6-10.
- [10]. Goda Y, Hoshino K, Akiyama H, Ishikawa T, Abe Y, Nakamura T, et al. Constituents in Watercress: inhibitors of histamine release from RBL-2H3 cells induced by antigen stimulation. *Biol Pharm Bull.* 1999; 22: 1319-26.
- [11]. Chung FL, Morse MA, Eklind KI, Lewis J. Quantitation of human uptake of the anticarcinogen phenethyl isothiocyanate after a watercress meal. *Cancer Epidemiol Biomarkers Prev.* 1992; 1: 383-8.
- [12]. Gill CI, Haldar S, Boyd LA, Bennett R, Whiteford J, Butler M, et al. Watercress supplementation in diet reduces lymphocyte DNA damage and alters blood antioxidant status in healthy adults. *Am J Clin Nutr.* 2007; 85(2):504-10.
- [13]. Getahun SM, Chung FL. Conversion of glucosinolates to isothiocyanates in humans after ingestion of cooked water cress. *Cancer Epidemiol Biomarkers Prev.* 1999; 8:447-51.
- [14]. World Health Organization WHO, "Laboratory manual for the examination of human semen and semen-cervical mucus interaction," 4th ed, Cambridge University Press, New York, 1999.
- [15]. Guneli E, Tugyan K, Ozturk H, Gumustekin M, Cilaker S, Uysal N. Effect of melatonin on testicular damage in streptozotocin-induced diabetes rats. *Eur Surg Res.* 2008; 40: 354-60.
- [16]. Cao L, Leers-Sucheta S, Azhar S. Aging alters the functional expression of enzymatic and non-enzymatic anti-oxidant defense systems in testicular rat Leydig cells. *J Steroid Biochem Mol Biol.* 2004; 88: 61-7.
- [17]. Aprioku JS. Pharmacology of Free Radicals and the Impact of Reactive Oxygen Species on the Testis. *J Reprod Infertil.* 2013;14:158-172.
- [18]. Cameron DF, Murray FT, Drylie DD. Interstitial compartment pathology and spermatogenic disruption in testes from impotent diabetic men. *Anat Rec.* 1985; 213: 53-62.
- [19]. Al-Attar AM. Antioxidant effect of vitamin E treatment on some heavy metals-induced renal and testicular injuries in male mice. *Saudi J Biol Sci.* 2011; 18:63-72.
- [20]. Chen CS, Chao HT, Pan RL, Wei YH. Hydroxyl radical induced decline in motility and increase in lipid peroxidation and DNA modification in human sperm. *Biochem Mol Biol Int.* 1997;43: 291-303.
- [21]. Vignon F, Le Faou A, Montagnon D, Pradignac A, Cranz C, Winiszewsky P, et al. Comparative study of semen in diabetic and healthy men. *Diabete Metab.* 1991; 17: 350-4.
- [22]. Predes FS, Monteiro JC, Paula TAR, Matta SLP. Evaluation of rat testes treated with arctium lappa I: Morphometric study. *Braz J Morphol Sci.* 2007; 24: 112-117.
- [23]. Mohammadi J, Chatroz B, Delaviz H. The Effect of Hydroalcoholic Extract of Capparis Spinosa on Quality of Sperm and Rate of Testosterone Following Induction of Diabetes in Rats. *Journal of Isfahan Medical School.* 2014; 31: 1-11.
- [24]. Mohammadi J, Delaviz H, Malekzadeh JM, Roozbehi A. The effect of hydro alcoholic extract of Juglans regia leaves in streptozotocin-nicotinamide induced diabetic rats. *Pak J Pharm Sci.* 2012; 25: 407-411.
- [25]. Ramaswamy S and Weinbauer GF. Endocrine control of spermatogenesis: Role of FSH and LH/ testosterone. *Spermatogenesis.* 2014; 4: e996025.
- [26]. Manach C, Morand C, Crespy V, Demigne C, Texier O, Regerat F, et al. Quercetin is recovered in human plasma as conjugated derivatives which retain antioxidant properties. *FEBS Lett.* 1998;426: 331-6.
- [27]. Khaki A, Fathiazad F, Nouri M, Khaki AA, Chelar C, ozanci, Ghafari-Novin M, Hamadeh M. The effects of ginger on spermatogenesis and sperm parameters of rat. *Iranian J of Reproductive Medicine.* 2009;7: 7 -12.
- [28]. Ozen T. Investigation of antioxidant properties of *Nasturtium officinale* (water cress) leaf extracts. *Acta Pol Pharm.* 2009;66:187-93.
- [29]. Gurel A, Coskun O, Armutcu F, Kanter M, Ozen OA. Vitamin E against oxidative damage caused by formaldehyde in frontal cortex and hippocampus: biochemical and histological studies. *J Chem Neuroanat.* 2005;29: 173-8.
- [30]. Verma A, Kanwar KC. Effect of vitamin E on human sperm motility and lipid peroxidation invitro. *Asian J Androl.* 1999; 1: 151.
- [31]. Aitken RJ, Roman SD. Antioxidant systems and oxidative stress in the testes. *Oxid Med Cell Longev.* 2008; 1: 15-24.
- [32]. Glade MJ, Smith K. Oxidative Stress, Nutritional Antioxidants, and Testosterone Secretion in Men. *Ann Nutr Disord & Ther.* 2015;2: 1-21.
- [33]. Hadjzadeh MA, Rajaei Z, Moradi R, Ghorbani A. Effects of Hydroalcoholic Extract of Watercress (*Nasturtium Officinale*) Leaves on Serum Glucose and Lipid Levels in Diabetic Rats. *Indian J Physiol Pharmacol.* 2015;59(2):223-30.
- [34]. Hoseini HF, Ahmad Gohari R, Saeidnia S, Naghi Shahabi M, Hadjiakhoondi A. The effect of *Nasturtium officinale* on blood glucose level in diabetic rats. *Pharmacology online.* 2009;3: 866-871.