

Toxicity Study of one Sidhha preparation, “*Nathai parpam*”

Rengasundari R¹, Ganesan A², Mudiganti Ram Krishna Rao³, Raguram Ganesan⁴

¹Associate Professor, Department of Nanju Noolum Maruthuva Noolum, National Institute of Siddha, Chennai-47.

²Lecturer, Government Siddha Medical College, Chennai-106.

³Professor, Department of Industrial Biotechnology, Bharath University, Chennai- 600073.

⁴U.G Scholar (MBBS), Jiamusi Medical University, Jiamusi, China.

Abstract

Nathai is the tamil name of snail, *Pila globosa*. Nathai Parpam is the ash prepared by the Snails and is used to treat anal bleeding, piles and rectal complications in Sidhha form of medical practice. There is dearth of knowledge about the toxicity aspects and medicinal efficacy for most of the contemporary and alternative forms of medicines. The present study is to ascertain the short and long term toxicity of this medicine on animal model. This study is all the more important since the Parpam is totally an inorganic material containing various metals and salts. It was observed that this medicine does not have any acute toxicity whereas it does indicate toxicity at chronic treatment. It is suggested that *Nathai parpam* can be safely used on a short term basis and chronic use should be avoided.

Key words *Nathai*, Parpam, *Pila globosa*, Toxicity, Sidhha, Acute, Chronic

INTRODUCTION

Efficacy standardization of Sidhha and other forms of contemporary and alternative medicine is the focus of attention in the light of modern day validation of medicines. It is a long way to go in this process. It is heartening that since last decade or so many reports in this direction have come, which is welcome sign. Some reports are available in this direction. [1-10] It is imperative to prove their efficacy by toxicological, pharmacological and pharmacokinetic aspects to bring them more acceptable. Although age old and time tested forms of medical practices, their acceptance at the global level is very limited due to the lack of such scientific data. Since these forms of medicines are ethno-pharmacologically used by majority of the humanity, their scientific validation is vital. Being in natural forms, these medicines are easily affordable, easily prepared and are supposed to have minimal side effects. In continuance of our endeavor in this direction, the present work encompasses the toxicological study of one Sidhha medicine, namely, “*Nathai Parpam*.”

Nathai parpam is a sidhha preparation as per classical Sidhha literature. This medicine is taken orally with ghee and is mainly used to cure rectal bleeding and piles. This is also used for ailments like T.B. and Diabetes. The present method of preparation of *Nathai parpam* was taken from the book “*Gunnepudham-Thatthu Jeeva Vagupu*” by Dr. R. Thiyagarajan, L.I. M. The work deals with the short term and long term toxicological effects of *Nathai parpam* on animal model. The preparation of the medicine and its toxicological studies of animal models are discussed.

MATERIALS AND METHODS

1. Collections of Snails.

Live fresh water snails, *Pila globosa* were collected and cleaned with fresh water thoroughly, to remove attached dirt and mud.

2. Collection of Fresh leaves of *Abutilon indicum* (Tutthi): Fresh leaves of *Abutilon indicum* were procured locally, cleaned thoroughly with water to remove mud and

dust and were ground well with distilled water. The paste was filtered and the filtrate was used in the process.

3. Preparation of *Nathai parpam*

Live fresh snails are half filled in an earthen pot and closed with cotton cloth pasted with clay. This clay cloth is known as “Seelai man”. Seven such clay cloths were used to cover the pot. The pot was dried in hot sun. A pit is made and in the ground and the pot was placed on it and it was heated with cow dung cakes, known as *Varaties*. This heating process is known as *Pudam*. Each cow dung cake weighed about 30 gm and 800 of them were used to heat the pot slowly. The pot was then cooled for a day and the ashes are collected. This ash was then ground well with the juice of *Abutilon indicum* leaves to make a paste. This paste was kept in the pot and heated as earlier and then cooled. This process was repeated three times and the final powder obtained was *Nathai parpam*.

4. Chemical Analysis of *Nathai Parpam*: The chemical analysis of *Nathai parpam* was conducted by standard methods to evaluate the presence of inorganic materials like Calcium, Zinc, Iron, Chloride, Carbonate and Phosphates.

PREPARATION OF THE EXTRACT

10 gm of the Parpam was weighed accurately and placed in a clean beaker and a few drops of concentrated Hydrochloric acid was added. This was allowed to cool and dry at room temperature. 100 ml of distilled water was added to it, stirred well and filtered. The filtrate was subjected to various analytical parameters.

5. Toxicity Studies:

A. Acute Toxicity:

The acute toxicity study was conducted on healthy Wistar white albino rats of both sexes. Each animal weighed about 80-120 gm and their age being approximately 12 weeks. Animals were maintained with standard animal food and water *ad libitum*. Animals were allowed to get accustomed to laboratory conditions by keeping them in cages for five days before starting the experiment. The temperature of the animal room was maintained at 25±°

Celsius and humidity at 30%. 12 hrs dark/light cycles were maintained. 12 rats were divided into 6 groups, each group consisting of 2 rats.

Dosage: Exact weight of the drug was taken, ground to fine powder and mixed thoroughly with Ghee (*Anupanam*, Adjuvant or Vehicle) for administration to animals orally. The animals were fasted for 12 hrs before administering the drug. The animals were fed after 3-4 hrs.

The following dose levels were fixed by presuming a range of least toxicity to maximum toxicity.

Group I: Control

Group II: 100 mg/ 100gm body weight

Group III: 200 mg/100gm body weight

Group IV: 400 mg/100gm body weight

Group V: 800 mg/100gm body weight

Group VI: 1600 mg/100gm body weight

The drug was weighed and suspended in pure ghee (processed butter) and administered orally, once a day. The following observations were recorded.

1. Stimulation: Hyperactivity, Pylo-erection, Twitching, Rigidity, Irritability, Jumping, Convulsions
2. Depression: Ptosis, Sedation, Sleep, Loss of Pinna reflex, Ataxia, Loss of muscle tone, Analgesia
3. Autonomic effects: Straub tail, Labored respiration, Cyanosis, Blanching, Reddening, Abnormal secretion.

All the above parameters were observed at 1 hr, 2 hr, 4 hr and 24 hr duration.

B. Chronic toxicity studies:

Since this medicine is administered to chronic patients usually for 90 days, it was decided to go for a chronic toxicity study on Wistar albino rats for the same period.

The chronic toxicity study was conducted on healthy Wistar white albino rats of both sexes. Each animal weighed about 80-120 gm and their age being approximately 12 weeks. Animals were maintained with standard animal food and water *ad libitum*. Animals were allowed to get accustomed to laboratory conditions by

keeping them in cages for five days before starting the experiment. The temperature of the animal room was maintained at $25 \pm ^\circ$ Celsius and humidity at 30% and 12 hrs dark/light cycles were maintained. 15 rats were divided into 3 groups, each group consisting of 5 rats.

Dosage: Exact weight of the drug was taken, ground to fine powder and mixed thoroughly with Ghee (*Anupanam*, Adjuvant or Vehicle) for administration to animals orally. The animals were fasted for 12 hrs before administering the drug. The animals were fed after 3-4 hrs.

The following dose levels were fixed by presuming a range of least toxicity to maximum toxicity. This study was conducted for 90 days to observe any adverse effects on hematological parameters on kidney and on liver.

Group I: Control

Group II: 100 mg/ 100gm body weight

Group III: 200 mg/100gm body weight

The drug was weighed and suspended in pure ghee and administered orally, once a day. The following observations were recorded.

1. Weight of the animal
2. Hematological indices: a. W.B.C. Total Count, b. W.B.C. differential Count and c. Haemoglobin

The results were collected on Ist day (0th Day), 30th day, 60th day and 90th day and were tabulated.

At the end of the experiment, the animals were sacrificed. The liver, kidney and heart were removed and preserved in 40% formalin for histo-pathological studies. The histological results are shown in Figure 1, 2 and 3.

RESULTS AND DISCUSSION

A. Chemical Analysis of *Nathai parpam*:

From Table 1 it is clear that the qualitative analysis of "*Nathai parpam*" indicated the presence of chemical constituents such as Calcium, Sulphate and Ferric ions. Although the presence of these ions is biocompatible and working for the homeostasis of the body, there specific curative activity in relation to piles is being studied.

Table1. Indicate the chemical analysis result of *Nathai parpam*.

Sl. No.	Experiment	Observation	Inference
1	Test for Calcium: 2 ml of extract was added to 2 ml of 4% Ammonium oxalate.	White precipitate was formed.	Presence of Calcium indicated.
2	Test for Sulphate: 2 ml of extract was added to 2 ml of 5% Barium chloride solution.	White precipitate was formed.	Absence of Sulphate is indicated
3	Test for Chloride: 2 ml of extract was treated with Silver nitrate solution.	Precipitate was not formed.	Absence of Chloride was indicated
4	Test for Carbonate: 2 ml of extract was treated with few drops of Conc. Hydrochloric acid	No effervescence was found	Indicating absence of Carbonate
5	Test for Zinc: 2 ml of solution was boiled with Conc. Hydrochloric acid	No white precipitate was observed	Absence of Zinc was indicated
6	Test for Ferric ion: 2 ml of extract was added with Potassium ferri cyanide	The solution showed blue color	Presence of Ferric ion was indicated
7	Test for Phosphate ion: The extract was treated with Ammonium molibdate and concentrated nitric acid	No yellow precipitate was formed.	Absence of phosphate was indicated

Table 2. Acute toxicity results of *Nathai parpam* on Wistar Albino Rats for Control, Group I and II.

Observations	Control				Group I				Group II			
	Gr1				100 mg/100 g BW				200 mg/100 g BW			
	At 1 hr	At 2 hr	At 4 hr	At 24 hr	At 1 hr	At 2 hr	At 4 hr	At 24 hr	At 1 hr	At 2 hr	At 4 hr	At 24 hr
Hyperacidity	N	N	N	N	N	N	N	N	N	N	N	N
Pyloerection	N	N	N	N	N	N	N	N	N	N	N	N
Twitching	N	N	N	N	N	N	N	N	N	N	N	N
Rigidity	N	N	N	N	N	N	N	N	N	N	N	N
Irritability	N	N	N	N	N	N	N	N	N	N	N	N
Jumping	N	N	N	N	N	N	N	N	N	N	N	N
Convulsion	N	N	N	N	N	N	N	N	N	N	N	N
Ptosis	N	N	N	N	N	N	N	N	N	N	N	N
Sedation	N	N	N	N	N	N	N	N	N	N	N	N
Sleep	N	N	N	N	N	N	N	N	N	N	N	N
Loss of Pinna Reflex	N	N	N	N	N	N	N	N	N	N	N	N
Ataxia	N	N	N	N	N	N	N	N	N	N	N	N
Loss of Muscle tone	N	N	N	N	N	N	N	N	N	N	N	N
Analgesia	N	N	N	N	N	N	N	N	N	N	N	N
Straup tail	N	N	N	N	N	N	N	N	N	N	N	N
Laboured Respiration	N	N	N	N	N	N	N	N	N	N	N	N
Cyanosis	N	N	N	N	N	N	N	N	N	N	N	N
Blanching	N	N	N	N	N	N	N	N	N	N	N	N
Reddening	N	N	N	N	N	N	N	N	N	N	N	N
No. Of Deaths	N	N	N	N	N	N	N	N	N	N	N	N

P = Positive; N= Negative

Table 3. Acute toxicity results of *Nathai parpam* on Wistar Albino Rats for Groups III, IV and V.

Observations	Group III				Group IV				Group V			
	400 mg/100 g BW				800 mg/100g BW				1600 mg/100 g BW			
	At 1 hr	At 2 hr	At 4 hr	At 24 hr	At 1 hr	At 2 hr	At 4 hr	At 24 hr	At 1 hr	At 2 hr	At 4 hr	At 24 hr
Hyperacidity	N	N	N	N	N	N	N	N	N	N	N	N
Pyloerection	N	N	N	N	N	N	N	N	N	N	N	N
Twitching	N	N	N	N	N	N	N	N	N	N	N	N
Rigidity	N	N	N	N	N	N	N	N	N	N	N	N
Irritability	N	N	N	N	N	N	N	N	N	N	N	N
Jumping	N	N	N	N	N	N	N	N	N	N	N	N
Convulsion	N	N	N	N	N	N	N	N	N	N	N	N
Ptosis	N	N	N	N	N	N	N	N	N	N	N	N
Sedation	N	N	N	N	N	N	N	N	N	N	N	N
Sleep	N	N	N	N	N	N	N	N	P	N	N	P
Loss of Pinna Reflex	N	N	N	N	N	N	N	N	N	N	N	N
Ataxia	N	N	N	N	N	N	N	N	N	N	N	N
Loss of Muscle tone	N	N	N	N	N	N	N	N	N	N	N	N
Analgesia	N	N	N	N	N	N	N	N	N	N	N	N
Straup tail	N	N	N	N	N	N	N	N	N	N	N	N
Laboured Respiration	N	N	N	N	N	N	N	N	N	N	N	N
Cyanosis	N	N	N	N	N	N	N	N	N	N	N	N
Blanching	N	N	N	N	N	N	N	N	N	N	N	N
Reddening	N	N	N	N	N	N	N	N	N	N	N	N
No. Of Deaths	N	N	N	N	N	N	N	N	N	N	N	N

P = Positive N = Negative

2. Acute Toxicity Studies: The results of acute toxicity studies are mentioned in Table 2 and Table 3. It was observed from the table 2 and 3 that *Nathai parpam* did not show any adverse effects on the various parameters studied at 100, 200, 400 mg/100g doses. At 800 and 1600 mg/100g dose there were mild signs of sleep that too after 24 hr of treatment. Mortality was not observed at the highest dose

also. It was not possible to calculate the LD50 values since treating with further higher doses was not practical on such small animal models.

3. Chronic toxicity Studies

The results of hematological indices and body weights of chronic toxicity studies are mentioned in Table 4. The

histopathological study results on kidney and liver are shown in Figures 1 to 4.

Table 4. Hematological Indices and Body weights of animals before and after treatment with *Nathai Parpam*

	Gr. I				Gr. II				Gr. III			
	0 th Day	30 th Day	60 th Day	90 th Day	0 th Day	30 th Day	60 th Day	90 th Day	0 th Day	30 th Day	60 th Day	90 th Day
1. Blood Parameters												
Total WBC Count No./cu mm	5100	5100	4900	4800	9100	7790	8500	8100	9300	9350	9400	9300
Neutrophils (%)	65	58	60	43	90	84	86	81	95	95	96	95
Basophiles (%)	0	0	0	0	0	0	0	0	0	0	0	0
Lymphocytes (%)	33%	42%	39	50	40	42	44	44	40	40	42	40
Monocytcs (%)	0	0	0	0	0	0	0	0	0	0	0	0
Hemoglobin (gm)	11	11.2	11.3	11.2	10.6	10.7	10.8	10.9	11	11.1	11.2	11.3
2. Body Weight(gm)												
	100	100	100	100	100	100	100	100	100	100	100	100

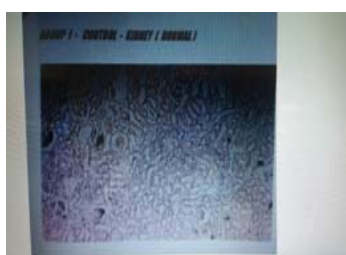

Fig.1 T.S. Kidney Control

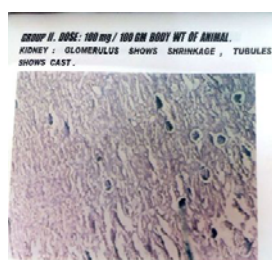

Fig. 2. T. S. Kidney of 100mg/100gm B. W.

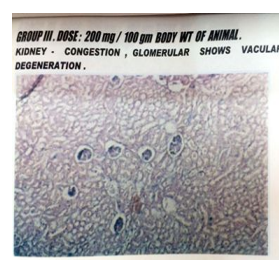


Fig. 3 T.S Kidney Of 200mg/100 gm B.W.



Fig.4 T.S. Liver Control

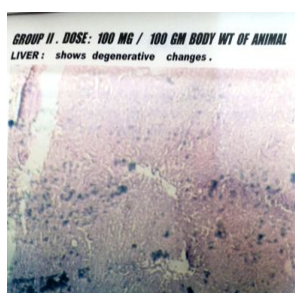


Fig. 5. T. S. Liver of 100mg/100gm B. W.

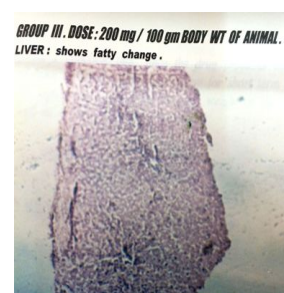


Fig. 6 T.S Liver Of 200mg/100 gm B.W.

From Table 4 it is clear that there was no perceptible changes in the hematological or body weight profiles on the animal models studies due to the treatment of 100 mg and 200 mg/100 gm body weight of animals (Group II and Group III) when compared to control animals.

It was observed that at 100 mg and 200mg/100gm doses the kidneys showed congestion, glomerulus shrinkage, vascular degeneration and the tubules show casts. (Figures 1, 2, 3) Likewise it was observed that liver became fatty and some degenerative changes occurred at 100 and 200 mg/ 100 gm doses when compared to the histopathology of the control group liver (Figure 4, 5, 6)

From the above results it is concluded that the drug, *Nathai Parpam*, produces toxic effects on long term use, such as kidney and liver damages whereas it is a safe drug if used as a short term therapy. Further work on other parameters is going on to prove the efficacy of this drug in a more elaborate way.

Acknowledgement

The authors would like to acknowledge all those persons who helped in this project directly or indirectly.

REFERENCES

- Sathish Kumar M, Ram Krishna Rao M, Ganesan A, Renga Sundari G. *Int J of pharmaceutical Science Res and Review*, 2013, 20(1), 140-141.
- Ram Krishna Rao Mudiganti, Ganesan, A., Renga Sundari G, M. Sathish Kumar, Neema Kuamri Jha. *Der Pharmacia Lettre*, 2014, 6 (3), 20-26.
- Mudiganti Ram Krishna Rao, Ganesan, A., Renga Sundari G, Sathish Kumar M., Neema Kumari Jha. *Der Pharmacia Lettre*, 2014, 6 (4), 5-7
- Mudiganti Ram Krishna Rao, Ganesan, A., Renga Sundari G, Sathish Kumar M., Neema Kumari Jha. 2014. *Der Pharmacia Lettre*, 6 (4), 27-29
- Mudiganti Ram Krishna Rao, Ganesan, A., Renga Sundari G., Sathish Kumar M., Neema Kumari Jha. *Der Pharmacia Lettre*, 2014, 5 (6), 71-77.
- Mudiganti Ram Krishna Rao, Hassan Mohammad, Sridhar Narayanan, Prabhu K, Kalaiselvi VS, Aparna Ravi, Hari Babu, Guru Rajan, Suganya S. *Int. J. Pharm. Sci. Rev. Res.*, 2016, 37(1), 19-25
- Aparna Ravi, Hassan Mohammad, Rao MRK, Prabhu K, Hari Babu, Shridhar Narayanan, Guru Rajan, Sanjay Singh. *International Journal of Pharmacy and Technology*. 2015, 7(3), 10091-10112
- Gunabadm thathu jeeva vakuppu - Dr. Thiyagarajan M . III rd Edition - 1992.